

The Incidence of Malignant Infiltration in the Biopsy Tract of Osteosarcoma

R Mohana*, M Med Ortho USM, **WI Faisham***, M Med Ortho USM, **W Zulmi***, M Sc Ortho UKM, **AS Nawfar***, M Med Ortho USM, **O Effat****, M Med Patho USM, **Salzihan MS**, MD**, M Med Patho USM

* Department of Orthopaedics, University Science of Malaysia, Kelantan, Malaysia

** Department of Pathology, University Science of Malaysia, Kelantan, Malaysia

ABSTRACT

Biopsy is a crucial step in the management of musculoskeletal sarcoma. The surgical approach to the biopsy site is important, as the tract must be removed en bloc with the tumour during limb sparing surgery so as to reduce the risk of local recurrence. The biopsy tracts of 26 osteosarcoma patients were evaluated histologically for tumour infiltration. Horizontal sections of 1 mm thickness with 2 cm radius from were evaluated from each excised biopsy tract. Five out of 26 cases (19.2%) showed positive tumour infiltration. One case (3.85%) had tumour infiltration in the pseudocapsule, two cases (7.69%) had tumour infiltration into the muscle and two other cases (7.69%) had tumour infiltration into the subcutaneous tissue. None had skin infiltration. We conclude that resection of the entire biopsy tract is indeed mandatory for surgical treatment of osteosarcoma.

Key Words:

Biopsy tract, Osteosarcoma, Histopathology

INTRODUCTION

Tissue biopsy, essential before an oncologist can decide on a treatment plan for musculoskeletal tumours, has prognostic implication as well as therapeutic consequences. It is always advisable that the biopsy be performed by the same surgeon who will likely perform further oncological surgery on the patient^{1,2}. Poorly performed biopsies, poorly placed incisions and complications of biopsy procedure can considerably compromise subsequent management of the tumour^{3,4}. However, there is insufficient information to guide practice regarding the incidence of malignant infiltration of tumour in biopsy scars.

The aim of this study is to evaluate the incidence of tumour infiltration in biopsy tracts of osteosarcoma in order to delineate the dimensions of a safe margin for resection during definitive tumour resection.

MATERIALS AND METHODS

Between June 2003 and June 2005, 26 patients with histologically confirmed osteosarcoma were treated at Hospital Universiti Sains Malaysia. Clinical and radiological records of the 26 patients were reviewed and it was found that tissue diagnoses were obtained in all cases, either by open or needle biopsy. Patients were staged according to Enneking's Staging System for musculoskeletal sarcomas⁵. Most patients received neo-adjuvant chemotherapy consisting of adriamycin and cisplatin as per protocol of the European Osteosarcoma Inter-group. Definitive surgery was usually performed after three cycles of chemotherapy, however, two patients with massive soft tissue involvements required amputation before initiating chemotherapy⁶.

Osteosarcoma specimens obtained from limb salvage surgery or amputation were sent for pathology evaluation in total. Evaluation of tumour border and percentage of tumour necrosis was performed as part of the treatment protocol. The needle tract and surgical scar for tissue biopsy were identified from the resected tumour specimen and sectioned in detailed. The biopsy scar was sectioned transversely at a distance of 3mm on the skin all the way down to fibrous tract until the pseudocapsule. Specimens were blocked in paraffin and sectioned at three-micron thickness, and then were stained with conventional haematoxylin and eosin in order to evaluate for the presence of tumour infiltration in the biopsy tract and if present, to measure the depth of infiltration. All tissue sections were evaluated by a single pathologist to minimise bias.

RESULTS

This study sample was composed of 16 male and 10 female patients, with a mean age of 18 years (range 6 to 43 years). The locations of primary tumour were: the distal femur, 12 patients; proximal tibia, 7; proximal humerus, 5; and distal radius in 2 patients. Classical osteoblastic osteosarcomas were seen in twenty-three patients. There were one case each

of telangiectatic, chondroblastic and fibroblastic osteosarcoma. Fourteen patients already had pulmonary metastases at the time of presentation. Twenty patients had thru-cut biopsy while the remaining had open biopsy. Twenty-four cases received neoadjuvant chemotherapy prior to surgery. Primary amputation was performed in the other two cases prior to chemotherapy due to massive soft tissue involvement at presentation. Eighteen patients underwent wide resection and reconstruction after neo-adjuvant chemotherapy, and amputation was performed in the remaining 4 who were poor responders to chemotherapy.

Five cases (19.2%) demonstrated histological evidence of tumour infiltration in the biopsy tract. One case showed infiltration to the pseudocapsule (Figure 3A), two had infiltration to the muscle layer (Figure 3B), and another two to subcutaneous tissue (Figure 3C). No skin infiltration was noted in this study. The mean radius of malignant infiltration was 1.5mm. (range between 1.0 – 2.0 mm). One-third (2/6) of open biopsy cases were found to have tumour infiltration into the biopsy tract as compared to 6.7% (3/20) for those having needle biopsy.

Upon histological examination, we found that five cases were osteoblastic osteosarcoma; 3 were telangiectatic osteosarcoma and 1 was fibroblastic osteosarcoma. Two patients who did not receive neo-adjuvant chemotherapy and three poor chemotherapy responders demonstrated positive tumour infiltration. There was no evidence of tumour infiltration in any of the patients with good response to chemotherapy. (Table I)

DISCUSSION

Biopsy is a key step in the diagnosis of musculoskeletal tumours and must be preceded by careful clinical evaluation

and analysis of all imaging studies. Biopsy procedure, if performed incorrectly, can have a negative impact in overall disease management. The position of the biopsy site within the lesion is quite significant due the fact that bone and soft tissue tumours may have regional morphological variants^{1,2}. The rate of major errors in diagnosis and biopsy complication can be reduced if the procedure is performed in specialized oncology centres by experienced clinicians^{3,4}.

Davies *et al.* reported a case of osteosarcoma that recurred in the needle biopsy tract⁷. In this case the biopsy tract could not be excised en bloc during the definitive surgery due to incorrect choice of the biopsy site. A nodule that appeared 4mm proximal to the visible biopsy scar 18 months after surgery was attributed to the needle biopsy tract itself, as there was no evidence of dissemination of disease to other sites⁷. Cannon and Dyson reported that 5 out of 13 (38%) patients, on whom the open biopsy scar could not be excised en bloc with the tumour, had local recurrence following resection and prosthetic replacement for malignant bone tumours. The incidence of local recurrence was much less when the tumour was excised en bloc (7%)⁸.

Just how widely biopsy scars should be resected remains a controversial area of oncological treatment. Simon recommends that wide margin resection of scars must be included as a surgical margin to minimise the risk of recurrence^{1,2}. However, malignant infiltration in the biopsy tract was noted to be approximately 1.0 – 2.0 mm into the muscle and pseudocapsule in the study where those suggestions were put forth. None of the cases showed evidence of skin infiltration.

Effective neo-adjuvant chemotherapy has revolutionised the management of osteosarcoma patients⁶. Chemotherapy-induced tumour necrosis has improved the success rate of limb-sparing surgery with less extensive radical margins without

Table 1: Comparison of cases of tumour infiltration in the osteosarcoma biopsy tract.

Number	Level of infiltration	Histological type	Method of biopsy	Response to chemotherapy
1	Pseudocapsule	Osteoblastic	Thru-cut	Amputation prior starting chemotherapy
2	Muscle	Osteoblastic	Open	Poor
3	Muscle	Osteoblastic	Thru-cut	Poor
4	Subcutaneous	Fibroblastic	Open	Poor
5	Subcutaneous	Telangiectatic	Thru-cut	Amputation prior starting chemotherapy

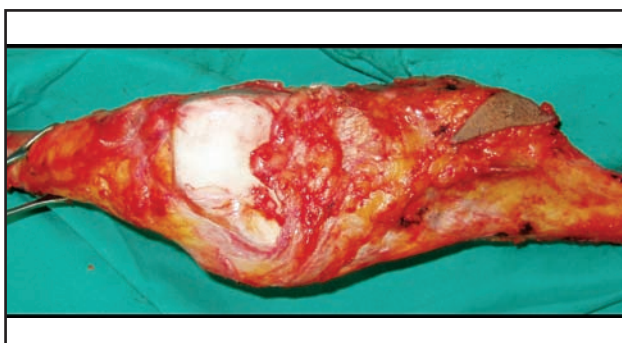


Fig. 1: Surgical specimen - osteosarcoma of the proximal tibia. Biopsy tract was removed en-bloc with the tumour.



Fig. 2: Close-up view of biopsy tract after slicing of surgical specimen.

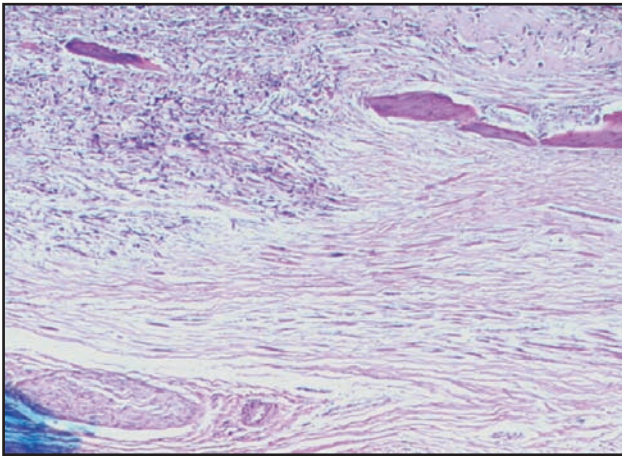


Fig. 3a

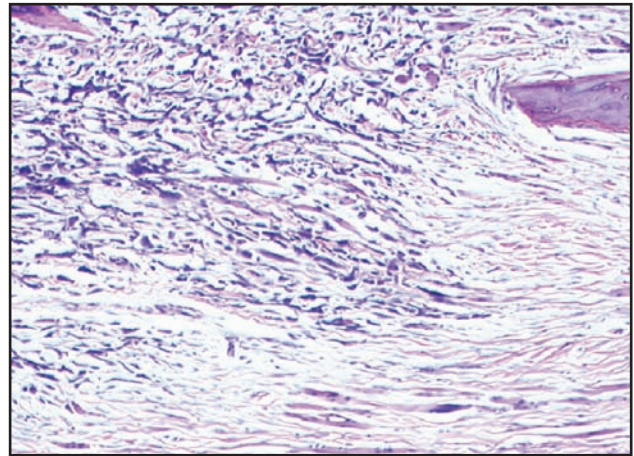


Fig. 3b

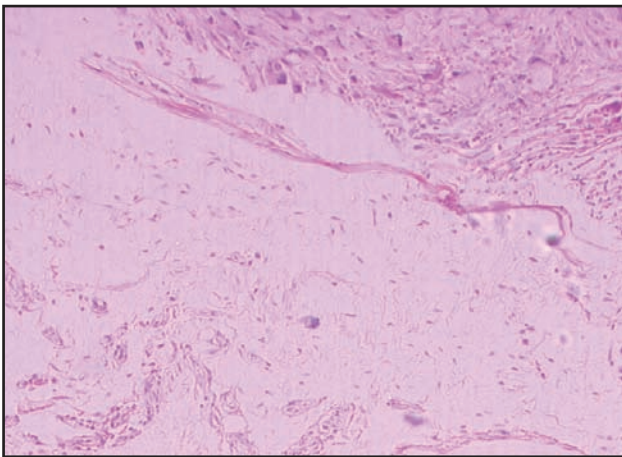


Fig. 3: Histological sections show tumour infiltration into A) the pseudocapsule, B) the adjacent muscle and C) the subcutaneous tissue.

any adverse impact on survival^{6,9}. Adjuvant chemotherapy has improved the success rate of limb salvage surgery and helps preserve optimum function of the affected limb. Additionally, this approach has a positive effect in the control of tumour infiltration at the biopsy site. Note that in the current study, we found no histological evidence of malignant infiltration of biopsy tracts in patients who had good response to chemotherapy.

Decisions regarding indication for open biopsy remain controversial. The open method allows larger tissue sampling, thereby facilitating diagnosis with accuracies as high 98%¹². Major disadvantages of open biopsy include the

increased risk of tumour seeding and higher complication rates^{1,2,3,4}. Closed thru-cut or core biopsy has become more popular due to its minimal complication rate and amenability as an out-patient procedure under local anaesthesia; however, these types of biopsies may spread tumour cells by violating anatomical barriers through the tract. The risk of local recurrence following tumour resection without excision of needle biopsy tract seems to be negligible^{10,11,12}. In 1991, Stroker reviewed 208 patients who underwent tumour resection without needle biopsy tract excision, and reported no local recurrences¹⁰. These findings are attributed to current practice by majority of oncology surgeons. However, this study was not supported by definite objective histological evaluation. In the current study, we found histological evidence of tumour infiltration in the thru-cut biopsy scars in chemotherapy responder patients. Nevertheless, the risk is lower with this method as compared to the open biopsy method.

CONCLUSION:

This study provided histological evidence of viable tumour along and around the biopsy tract at the time of definitive tumour resection. Resection of the entire biopsy tract is indeed recommended for optimal surgical treatment of osteosarcoma.

ACKNOWLEDGEMENT:

The study was funded by short term grant University Sains Malaysia 304/PPSP/6131385

REFERENCES

1. Simon MA. Current concepts review: Biopsy of musculoskeletal tumors. *J. Bone Joint Surg.* 1982; (64A): 1253-7.
2. Simon MA, Bierman JS. Biopsy of Bone And Soft Tissue Lesions. *J. Bone Joint Surg.* 1993; (75A) ICL: 616-21.
3. Mankin HJ. The hazards of biopsy in patients with malignant primary bone and soft tissue tumours. *J. Bone Joint Surg.* 1982. (64A): 1121-7.
4. Mankin HJ, Simon MA. The hazards of biopsy, revisited. *J. Bone Joint Surg.* 1996. (78A): 656-63.
5. Enneking WF, Spanier SS, Goodman MA. A system for the surgical staging of musculoskeletal sarcoma. *Clin. Orthop.* 1980. (153): 106-20
6. Bramwell VH, Burgers M, Sneath R, Souhami R, Van Oosteron AT, Voute PA, et al. A comparison of two short intensive chemotherapy regimens in osteosarcoma of limb in children and young adult: The study of the European Osteosarcoma Intergroup. *J. Clin. Oncol.* 1992. (10): 1579-91
7. Davies NM, Livesly PJ, Cannon SR. Recurrence of an osteosarcoma in a needle biopsy tract. *J. Bone Joint Surg.* 1993. (75B): 977-8.
8. Cannon SR, Dyson PHP. Relationship of the site of open biopsy of malignant bone tumours to local recurrence following resection and prosthetic replacement. *J. Bone Joint Surg.* 1987; Proceeding(B): 42
9. Tsuchiya H, Tomita K, Mori Y, Asada N, Yamamoto N. Marginal excision for osteosarcoma with caffeine assisted chemotherapy. *Clin. Orthop. Rel. Res.* 1999. (358): 27-35.
10. Stoker, DJ. Needle biopsy of musculoskeletal lesions: A review of 208 procedures. *J. Bone Joint Surg.* 1991. (73B): 498-500.
11. Schwartz HS, Spengler DM. Needle tract recurrences after closed biopsy for sarcomas: three cases and review of the literature. *Ann. Surg. Oncol.* 1997. (4): 228-36.
12. Michael AA, Alan W, Yasko, Ayala AG. Excision of the needle tract biopsy: Is it necessary? *AAOS.* 1995: 053.