

Neglected Posterior Elbow Dislocation Long Term Result Treated by Open Reduction

WIROON LAUPATTARAKASEM, M.D., BUNJONG MAHAISAWARIYA, M.D.,
SUKIT SAENGNIPANTHKUL, M.D.

*Department of Orthopaedics, Faculty of Medicine, Khon Kaen University,
Khon Kaen 40002, Thailand.*

ABSTRACT: A retrospective study of 32 cases of neglected posterior elbow dislocation openly reduced during 1976 and 1986 is presented. The mean follow-up period is 37.5 months (range 12 and 132 months). Speed technique was mainly used in the operation. A five-fold improvement of the final elbow flexion and arc of motion were obtained in comparison with the pre-operative values; though there was also increase in extension lag but as a whole the operated elbow became more functional for daily living activities. There is no correlation between the duration of dislocation and motions before operation, the former and postoperative final motions, as well as the pre-operative and postoperative final motions. All in all, open reduction in neglected elbow dislocation is generally beneficial irrespective to the duration of dislocation and motions presented before surgery.

While simple dislocation of the elbow is usually treated conservatively with a good result¹ a neglected case is more controversial about treatment method and prognosis, which are often considered to have correlation with the time elapsed after the initial injury. Some authors recommended that to warrant a good result, open reduction should be performed earlier than two to three months²⁻⁵ preferred salvage procedures if this was seen late in adults. Wadsworth⁶ stated that old dislocations consulted after many months should not be operated; while Naidoo⁷ and Foweles et al.⁸ thought that open reduction was always worth trying, at least in children.

In Thailand, neglected cases of elbow dislocation are not uncommon. These are usually resulted from malpractice of the primitive bone setters, who immobilize the dislocated elbow in extended position using bamboo splint (Figure 1). The pa-

tient later consults an orthopaedic surgeon because of the limited motion.

This paper reports personal experiences in open reduction of dislocations seen not earlier than one month that could be followed-up for at least 12 months.

MATERIALS AND METHODS

Over an 11-year period from 1976 to 1986, sixty-one cases of old posterior elbow dislocation had been operated on for reduction at Srinagarind Hospital, Khon Kaen University, Thailand. Only those 32 cases who met the conditions introduced above were reviewed. Details are given in Table 1. These included 20 male and 12 female patients, aged between seven and 75 years (average 26.2 years). Thirteen involving right elbow and 19 the left. There were five who had concomitant medial




Fig. 1 Bamboo splint (a) and its application for immobilization of the dislocated elbow by bone setters (b).

Table 1

Case	Side	Age (year), Sex	Duration of dislocation (month)	Before operation Flexion-extension (degree)	Length of follow-up (month)	Final Flexion-extension (degree)	Associated injuries	Other procedure	Post- operative Complications
1	R	14, M	2	10 - 20 (10)	132	10 - 135 (125)			
2	L	7, M	1	0 - 5 (5)	78	75 - 105 (30)			
3	R	57, M	2	0 - 10 (10)	78	5 - 140 (135)			UP
4	L	25, F	60	5 - 30 (25)	60	30 - 135 (105)		AT	
5	L	38, M	4	10 - 10 (0)	48	25 - 120 (95)			
6	L	25, M	3	0 - 10 (10)	42	50 - 115 (65)		AT	
7	R	19, M	6	10 - 40 (30)	60	60 - 90 (30)			NO, P
8	R	10, M	7	5 - 60 (55)	38	30 - 120 (90)			
9	L	19, F	2	0 - 10 (10)	18	25 - 110 (85)			UP, P
10	R	38, F	2	10 - 30 (20)	66	55 - 135 (80)			UP
11	L	11, F	2	0 - 10 (10)	30	60 - 130 (70)	FM		
12	L	12, M	2	10 - 20 (10)	24	60 - 105 (45)			
13	L	17, M	6	30 - 45 (15)	20	25 - 105 (80)	FM, UP	AT	
14	R	20, M	4	0 - 20 (20)	24	25 - 110 (85)			SN
15	R	18, M	3	15 - 30 (15)	54	55 - 125 (70)			P
16	L	9, F	1	0 - 10 (10)	53	75 - 110 (35)			P
17	L	19, M	4	0 - 10 (10)	47	60 - 120 (60)	FM		
18	R	8, M	2	0 - 20 (20)	13	45 - 130 (85)	FM		
19	L	18, M	1	0 - 10 (10)	36	30 - 140 (110)			
20	R	13, F	6	30 - 60 (30)	32	45 - 150 (105)		AT	
21	L	45, M	4	5 - 35 (30)	17	0 - 140 (140)			
22	L	52, M	3	0 - 15 (15)	24	40 - 140 (100)			
23	R	23, F	60	20 - 30 (10)	22	70 - 100 (30)			P
24	L	11, F	4	10 - 20 (10)	18	55 - 140 (85)			
25	R	43, F	1	5 - 30 (25)	12	5 - 150 (145)			
26	L	26, M	4	0 - 30 (30)	14		55 - 140 (85)		
27	R	20, M	4	5 - 20 (15)	54	0 - 135 (135)			
28	R	60, M	1	10 - 30 (20)	38	10 - 145 (135)			
29	L	22, F	3	5 - 20 (15)	12	30 - 120 (90)			UP
30	L	75, F	1	45 - 50 (5)	12	25 - 140 (115)	FM		
31	L	11, M	1	10 - 15 (5)	12	40 - 130 (90)			
32	L	52, F	3	10 - 30 (20)	12	5 - 130 (125)			

FM = Fracture of the medial epicondyle

UP = Ulnar nerve palsy

AT = Anterior transplant of ulnar nerve

MO = Myositis ossificans

SN = Skin necrosis

P = Pain on weight carrying

epicondylar fracture and one of them had ulnar nerve palsy, but none sustained an intraarticular fracture. The patients were first seen between one and 60 months (average 6.5 months) after dislocation. The range of elbow flexion-extension was measured preoperatively in every case, and an open reduction was performed without preliminary attempt at closed reduction by manipulation or continuous traction.

Operative technique

Mainly the technique described by Speed⁹ was followed. When flexion was less than 60 degrees, a long enough inverted V-flap of tricipital aponeurosis was always developed. It is very important to protect the ulnar nerve before releasing the posterior contracture to avoid accidental damage to this structure. The olecranon could be easily

identified, whereas the radical head was usually embedded in a fibro-osseous mass higher up over the posterior humeral cortex. In most cases, the articular surface was covered by fibrosis and certain degrees of degeneration had occurred. The fibrous tissue had to be gently removed to clean the joint cavity, any contracted elements were released by sharp dissection rather than by brisement force; this often ended up with complete division of both collateral ligaments and capsule. Reduction should be gentle and levering using a periosteal elevator was found to be helpful for the task. Post-reduction stabilities were always manually tested; mediolateral instability was acceptable since formation of fibrous tissue could stabilize the joint later, but should redislocation occurred when it was less than 90 degrees flexion, a small transfixing Kirschner pin was applied across either the humeroulnar or humeroradial joint, leaving the end of the pin protruded through the skin. When the ulnar nerve was obviously under tension at this position (cases 4, 6, 20) or had it been already injured (case 13), an anterior transplant was per-

formed. The tricipital aponeurotic flap was finally sutured in an inverted V-Y plasty manner to compensate for the shortening. A common feature was that the flap was usually too small to cover the posterior joint surface, but this had not produced other significant trouble and there had been no problem about adequacy of the lengthening provided by this method.

A well-padded posterior plaster slab was applied postoperatively until the transfixing pin was removed later at two weeks. Active range of

TABLE 2

Means and standard errors in degrees of elbow motion (n = 32) and statistical significance by paired student's t-test

Conditions	Preoperative	Postoperative	P-values
Flexion	24.5 ± 2.6	126.3 ± 2.8	< 0.001
Extension	-8.1 ± 1.8	-36.9 ± 4.0	< 0.001
Arc of motion	16.4 ± 1.9	89.4 ± 5.9	< 0.001

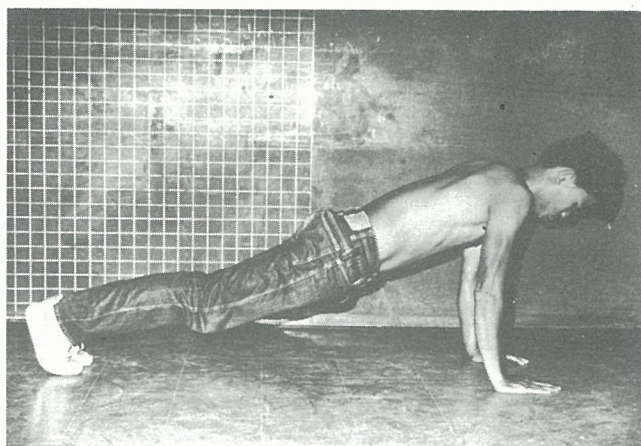

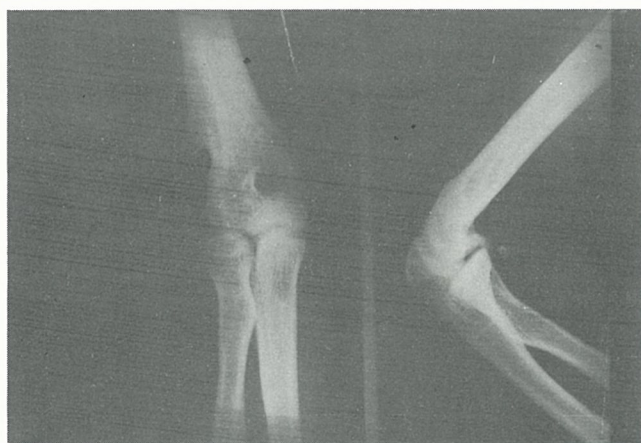


Fig. 2 Final results of the patient with 132-month follow-up period (case 1); (a) anteroposterior and lateral views of roentgenograms of the right elbow and (b, c) the patient demonstrating a push-up exercise.

motion exercise was then instructed as a home program and supervised periodically at the follow-up clinic.

RESULTS

The patient's last visit was between 12 and 132 months (average 37.5 months) after the operation. Final motions had been stable and the results are shown in Table 1. These are compared to the corresponding preoperative values by paired student's t-test which shows a very significant improvement ($P < 0.001$) in flexion and arc, although there was more extension lag (Table 2). Final results of the patient with longest follow-up (case 1) were demonstrated (Figure 2).

Postoperative complications were established in four patients (cases 3, 9, 10, 29) who developed an ulnar nerve palsy which recovered completely in a few months thereafter. The same was true for case 13 whose ulnar palsy had developed before the operation. One patient (case 7) developed a myositis ossificans which also had a poor final motion, and another (case 14) had superficial skin necrosis that healed in a few weeks by local treatments. No Kirschner wire track infection was observed and

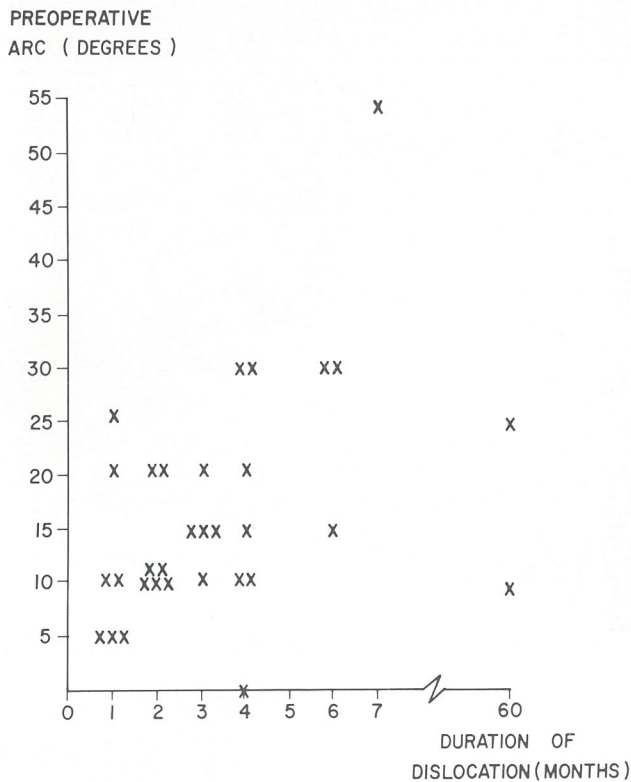


Fig. 3 Correlation between duration of dislocation and preoperative arc of motion, $r = 0.11$, $P = 0.56$

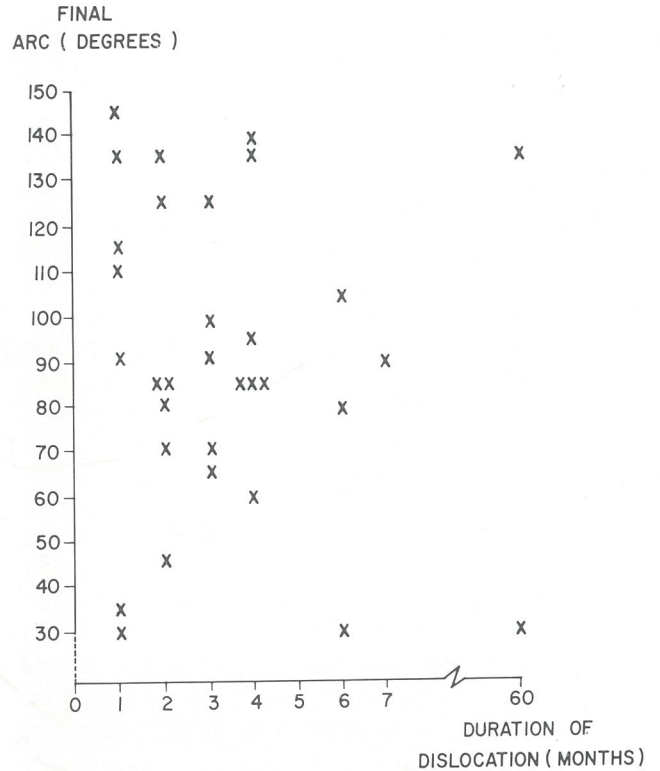


Fig. 4 Correlation between duration of dislocation and postoperative arc of motion, $r = -0.18$, $p = 0.32$

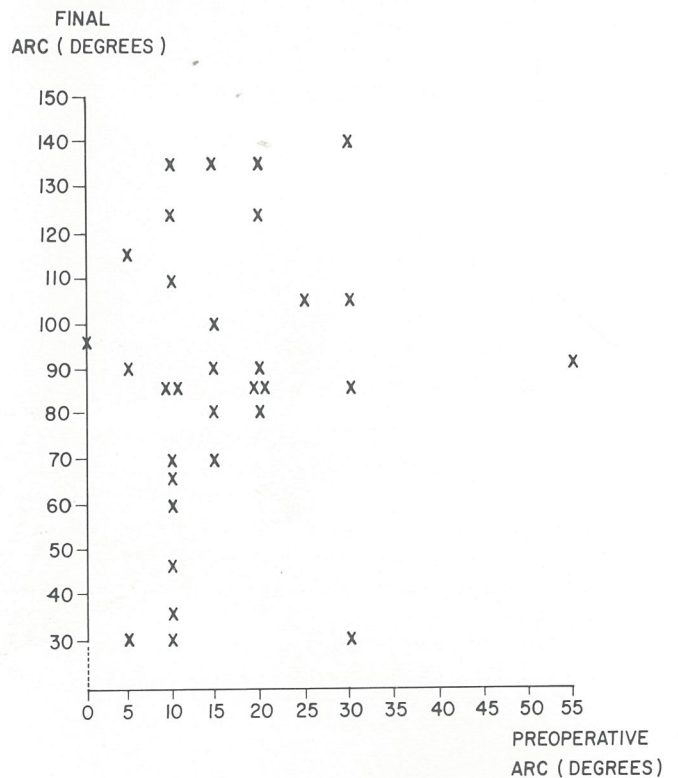


Fig. 5 Correlation between preoperative and postoperative arc of motion at final follow-up (mean = 37.5 months), $r = 0.13$, $p = 0.49$

there was also no record concerning patient's complaint about joint instability. There were five cases (cases 7, 9, 15, 16, 23) who experienced pain on carrying heavy object, all of them had a flexion deformity from 25 to 75 degrees and degenerative changes of the joint were also demonstrated by roentgenograms. Study of correlation between duration of dislocation before surgery and preoperative (Figure 3) as well as postoperative arc of motion (Figure 4) shows that correlation coefficients (r) are 0.11 ($p = 0.56$) and -0.18 ($p = 0.32$) respectively. For those between preoperative and postoperative motions (Figure 5), it is 0.13 ($p = 0.49$). All of these indicate that there are no significant correlation between the testing pairs (correlation coefficients are not significantly different than zero).

DISCUSSION

Both preoperative and final postoperative motions in this study were comparable to results reported by Krishnamoorthy et al.² and Naidoo.⁷ Following an open reduction, there was about five-fold improvement of flexion and arc of motion that led to a better functional position for daily living activities according to a study reported by Morrey et al.¹⁰ The increase of extension lag was likely a positional effect of the postoperative immobilization and weakness of triceps from leng-

thening; apart from degenerative process, this increase could also contribute to pain during weight carrying by stretching of the joint. It is noticeable that there is no significant correlation between the duration of dislocation and motions before operation, the duration of dislocation and postoperative final motions, as well as the preoperative and postoperative final motions. This is different from what was stated by Billett¹¹ and Freeman III¹² that the range of flexion obtained after surgery decreased proportionally to the length of time elapsed since injury, but agrees with Naidoo⁷ and Fowles et al.⁸ that open reduction should always be tried; this is irrespective to the duration of dislocation and the range of motion presented before surgery.

In conclusion, results of open reduction in neglected elbow dislocation are generally beneficial. However, it is difficult to predict preoperatively by considering duration of dislocation and presenting joint motion of the elbow. Other parameters necessary for prognosis await further investigation.

ACKNOWLEDGEMENTS

The authors wish to thank staffs of the Department of Orthopaedics and the Clinical Epidemiology Unit, Faculty of Medicine, Khon Kaen University for their comments; Prof. Dr. Somboon Srungboonmee for his help in preparing the manuscript.

REFERENCES

1. Josefsson PO, Johnell O, Gentz CF. Long-term sequelae of simple dislocation of the elbow. *J Bone Joint Surg (Am)* 1984; 66A:927-30.
2. Krishnamoorthy S, Bose K, Wong KP. Treatment of old unreduced dislocation of the elbow. *Injury* 1976; 8:39-42.
3. Delee JC, Green DP, Wilkins KE. Fractures and dislocations of the elbow. In: Rockwood CA Jr, Green DP, eds. *Fractures in adults*. Philadelphia: JB Lippincott, 1984:609.
4. Silva JF. Old dislocations of the elbow. *Ann R Coll Surg Engl* 1958; 22:363-81.
5. Wilson JN, ed. *Watson-Jones Fractures and joint injuries*. Edinburgh, Churchill Livingstone, 1982:632-5.
6. Wadsworth TG. *The elbow*. Edinburgh: Churchill Livingstone, 1982:186-7.
7. Naidoo KS. Unreduced posterior dislocations of the elbow. *J Bone Joint Surg (Br)* 1982; 64B:603-6.
8. Fowles JV, Kassab MT, Douik M. Untreated posterior dislocation of the elbow in children. *J Bone Joint Surg (Am)* 1984; 66A:921-6.
9. Speed JS. An operation for unreduced posterior dislocation of the elbow. *South Med J* 1925; 18:193-8.
10. Morrey BF, Askew LJ, An KN, Chao EY. A biomechanical study of normal functional elbow motion. *J Bone Joint Surg (Am)* 1981; 63A:872-7.
11. Billett DM. Unreduced posterior dislocation of the elbow. *J Trauma* 1979; 19:186-8.
12. Freeman BL 3rd. Old unreduced dislocations. In: Crenshaw AH, ed. *Campbell's operative orthopaedics*. St Louis, etc: CV Mosby, 1987: 2169-70.