

Avascular Necrosis of Femoral Head

M Y Tan*, Y J Wu*, B Y Low**

**Yong Loo Lin School of Medicine, National University of Singapore*

***Department of Orthopaedic Surgery, Changi General Hospital
Singapore*

ABSTRACT

Avascular necrosis (AVN) of the femoral head is a debilitating disease, which usually leads to progressive destruction of the femoral head and the acetabulum in patients who are in their 3rd to 5th decades of their life. This condition is bilateral in over 60% of cases, and in approximately 15% other bones are also affected, most frequently the humeral head, knee, talus, and small bones of the hand.

It is imperative that we detect this condition in its early stages because early intervention can greatly improve the prognosis.

Here, we will discuss about the patho-etiological process of avascular necrosis, investigations, diagnosis, staging and treatment modalities. We also present 4 cases of patients who were diagnosed with avascular necrosis of the head of femur. Hopefully, this paper would be able to increase our awareness as well as broaden our understanding of this condition.

INTRODUCTION

Avascular necrosis of the femoral head, also known as osteonecrosis or aseptic necrosis, is essentially a poorly understood pathological process, resulting from interruption of blood supply to bone. Avascular necrosis of the hip is poorly understood but it is the final common pathway of traumatic or non-traumatic factors that compromise the already precarious circulation of the femoral head. Femoral head ischemia then results in the death of marrow and osteocytes and usually results in the collapse of the necrotic segment.

Interestingly, studies have shown that the average age of patients presenting with this condition and undergoing total hip replacement is usually 38 years³⁵. This poses a huge problem because it is very unlikely that the current prosthetic implants will function for the remaining years of their lives⁶. Eventually, all these may put a strain on society, with the young workforce requiring further revisions. Thus, it is imperative that we look for other alternatives to delay or even eliminate the need for total hip replacement, preferably with procedures which preserve the femoral head^{26,33,37}.

Pathogenesis and Etiology

As previously mentioned, there is a disruption of the normal blood circulation to the femoral head. Within 6 to 12 hours after the vascular insult, death of marrow elements results. Initially, the bone is affected, but it may not be

apparent for several days. Next, repair begins to take place. Necrotic bone is removed while new bone is formed directly on the dead trabeculae.

Due to the removal of necrotic segment being more than that of bone formation, mechanical weakness results¹⁷. If the affected area is small and not near to a weight bearing surface, spontaneous healing is possible. However, in instances where the area affected is significant, and it is in a region of high stress, healing would be most unlikely, and collapse usually take place within 6 to 12 months. Avascular necrosis of the femoral head can be either primary (idiopathic) or secondary. In the past, 15%-20% of cases have been labeled as idiopathic, but with increasing knowledge of etiological factors, this number is gradually decreasing. Secondary avascular necrosis of femoral head could be due to (1) traumatic or (2) non-traumatic causes.

In traumatic cases, the pathology is a result of tearing of the vessels supplying the femoral head in fractures, and mechanical compression due to dislocations.

Non-traumatic osteonecrosis of femoral head could occur by the following mechanisms: (1) intra-osseous venous hypertension with secondary compartment syndrome, (2) extrinsic vessels pressure from fat cells (Gaucher's disease¹⁶ and corticosteroids – dosage levels of prednisolone above 30mg per day for at least 30 days have been shown to be of etiological significance³⁰), and (3) internal vessel thrombo-embolic injury i.e. sickle cell disease¹⁶, Caisson disease. Other conditions associated with avascular necrosis would include alcoholism (Jones reported that the threshold for ingestion of 100% ethyl alcohol to be at least 400 ml per week with a cumulative dose of 150L²⁹), coagulopathy¹⁸ (protein C deficiency, thrombophilia-hypofibrinolysis disorders), Perthes Disease⁵, inflammatory bowel disease²⁴, hyperlipidemia¹⁵, vasculitis⁴².

Diagnosis

Early diagnosis is imperative as the prognosis increases with early intervention before the femoral head collapses. As such, the important factor to consider in making a diagnosis is to have a high index of suspicion, and to be aware of the possible risk factors, which the patient might have at the time of presentation.

History and physical examination

The clinical presentation of the avascular necrosis is non-specific. Initial phases of avascular necrosis would usually go undetected. Pain starts to develop gradually and is usually intermittent and throbbing in nature. Pain could be secondary to increased intra-osseous pressures. Besides experiencing pain over the groin, individuals may also

complain of limited movements, and swelling over the affected hip. On clinical examination, there may be an antalgic gait, with positive Trendelenberg's sign, as well as limited range of motion, and tenderness over the affected area. Pain may be especially aggravated on internal rotation of the hip.

Radiographic investigations

Normal routine laboratory investigations are essentially negative. Most of the time, radiological imaging is the best method of detecting the pathology. Evaluation with antero-posterior and frog-leg lateral radiographs is essential for identification of lesions. Plain X-rays usually appear normal in the early stages, but changes would be noted as the disease progresses, such as increased density or radiolucency of the femoral head. With further progression, the pathognomonic crescent sign would become visible.

In situations where X-ray show pathognomonic changes, which are consistent with diagnosis of avascular necrosis, no further imaging is required. Even so, plain radiographs may be inadequate for evaluation of the extent of the disease due to variability in observer grading²⁰.

Bone Scanning

Technetium-99 methylene-diphosphonate bone scans are useful techniques, which help to identify infarcted regions due to increased uptake of the isotope on delayed image. This represents accumulation of the radionuclide in the area of increased bone turnover at the junction between reactive and dead bone. Even though Tc-99 scans may not be specific for avascular necrosis, a photopenic area surrounded by an area of increased activity is most consistent with the condition¹⁴. However, it is a less sensitive method of detecting early stages of the disease⁴³. Nonetheless, because of its lower cost as compared to MRI, it can be recommended in those who have a negative X-ray, no risk factors and unilateral symptoms.

Magnetic resonance imaging

The diagnosis of avascular necrosis of the femoral head is best made with the use of an MRI, which is more accurate as compared to plain X-rays^{9,13,21,22,37,38,41}. The earliest finding in avascular necrosis of femoral head is low intensity signal on T1-weighted images that could be representing the separation of normal and ischemic bones. In addition, T2-weighted images would show another high intensity signal line which is found within this line, and is thought to be due to granulating tissue, also known as double-line signal^{21,22,28}. MRI is also useful in monitoring the progression of the disease, as well as evaluating the efficacy of treatment, even though X-rays could also be used as a cheaper alternative. It also allows determination of the exact stage and extent of the pathological process without the utilization of any invasive procedures.

If avascular necrosis is suspected, but not detected on X-rays, or if the pathology is only seen in 1 hip, MRI of both hips is mandatory.

Functional evaluation of bone

Core biopsy, venography and the measurement of intra-osseous pressure represent the function evaluation^{7,25}. Despite having a high degree of sensitivity and specificity,

they are invasive procedures which should be attempted only when MRI, bone scans or X-rays produce findings which are inconsistent with the clinical impression, especially when there are co-existing risk factors in the individual.

Classification

Staging of avascular necrosis is imperative to determine the type and extent of involvement. This would allow the prognosis to be established, and also determine the appropriate modality of treatment. In addition, it enables the monitoring of progression or resolution of the condition, and the evaluation of the effectiveness of treatment, both in clinical practice and in conducted studies.

Various classification systems have been described, but the most commonly used at present was initially described by Arlet & Ficat in the 1960s. The latest version is below (Table 1):

Table 1: Staging of avascular necrosis

Stage		Clinical features	Radiographic signs
Early:			
0	Preclinical	0	0
I	Pre-radiographic	+	0
II	Before flattening of femoral head	+	Diffuse porosis, or sequestrum formation, sclerosis, or cysts
Transition:			
			Flattening; Crescent sign
Late:			
III		++	Broken contour of head, sequestrum, joint space normal
IV		+++	Flattened contour, decreased joint space, collapse of head

The international classification introduced by the Association of Research Circulation Osseous (ARCO) helps to standardize the approach to staging the disease and to allow more consistent reporting in the future. ARCO divides the disease into 5 stages:

Stage 0 : histology only

Stage 1 : with a positive diagnostic test (MRI)

Stage 2 : with a positive X ray with no radiographic collapse

Stage 3 : positive X-ray with collapse of the head of femur

Stage 4 : positive X-ray with osteoarthritis

Each stage can be further classified according to the percentage of femoral head involvement of surface collapse:

Subclass A: minimal with less than 15% femoral head involvement or less than 2 mm surface collapse

Subclass B: moderate with 15-30% head involvement or with 2-4 mm surface collapse

Subclass C: extensive with more than 30% femoral head involvement or with more than 4 mm surface collapse.

Treatment

The natural history of avascular necrosis of the femoral head is still poorly understood, but most studies have shown that symptomatic hips with Ficat stage I or II disease undergo collapse in more than 85% of cases at two years. There are still many controversies about the treatment of avascular necrosis. Generally, primary prevention is the best method, but being an elusive disease makes this very difficult. Nonetheless, associated risk factors such as alcohol consumption and steroid administration should be minimized. Patient education should be concise, yet simple to understand. This is important especially in individuals who require long term steroid therapy for conditions such as SLE, rheumatoid arthritis, and other autoimmune mediated disorders.

Treatment can be broadly classified into early and late treatment.

Early treatment of avascular necrosis

1. Conservative treatment, such as crutch ambulation or bed rest, is generally ineffective. However, it is indicated as a symptomatic treatment for those where prophylactic surgery is not indicated, and those who are not yet ready for hip replacement. This would include individuals with early and advanced stages of avascular necrosis. However, core decompression is usually advocated in early disease. Results have shown that core decompression is more effective as compared to symptomatic treatment with a pre-collapsed avascular necrosis of femoral head (Ficat stage-I and II) showing a success rate of 71% versus 34.5%¹⁰.

2. Some authors have also reported attempts to treat vascular necrosis with pharmacological intervention. Drugs include Hydergine (ergoloid mesylates), naftidrofuryl, and vincamine. Naftidrofuryl was able to reduce bone marrow pressures in 6 of 9 patients, while the systemic pressures remain the same³. Several trials are being conducted in the search of an agent which is able to treat this disease^{11,12,31}.

3. Experimentally, electrical stimulation has shown to be able to induce and enhance revascularization and osteogenesis. It also alters the osseous turnover¹, and all the aforementioned qualities may be effective in the treatment of avascular necrosis. A few studies have shown good results with adequate pain relief.

Electrical stimulation could also be applied together with core decompression. There had been varying results but this coupling procedure had yielded better results as compared to core decompression alone. However, additional studies are needed to define the application, timing and dosage of electrical stimulation.

4. Core decompression is an effective procedure which was first described by Arlet & Ficat in 1964, and a rationale was

eventually developed for the therapeutic role in which it could play, in the reduction of bone marrow pressure and improvement of intra-osseous blood circulation. At the same time, it provides immediate pain relief. Studies have shown good results in Ficat stages I and II hips treated with core decompression, but not so in more advanced stages³.

5. Non-vascularized bone grafts could also be placed within the core track of the femoral head to provide better structural support to the subchondral bone and articular cartilage during the process of healing after core decompression. Buckley et al.⁴ has reported excellent results in 90% of twenty hips which had Ficat stage I or II disease. More complex procedures include the trapdoor and light bulb procedures. Excellent results were shown in Ficat stage II and III disease^{34,33,27}.

6. Free vascularized fibular grafting is a relatively new technique which involves the removal of a segment of fibula with attached vascular pedicle, and is anastomosed to the lateral femoral circumflex artery and vein (Figure 1). The presence of a fibular graft does not exclude conversion to a total hip arthroplasty in the future, and there is no increased risk of infection.

If the procedure is done before collapse of the femoral head, there is a possibility that the graft will be viable for the life of the patient. In addition to its decompression effects, it also provides a strut mechanical support, and at the same time, enhances revascularization and introduces osteoprogenitor cells into the avascular region. There had been a diversity of opinions for vascularized bone grafting used in the treatment of avascular necrosis (Ficat stage II or III). Nonetheless, it may be a valuable option for young patients with Ficat stage II or III avascular necrosis with about 80% of patients doing well on long term follow up¹⁹.

7. In angulation or rotational (Sugioka) osteotomy, the necrotic region is shifted away from the weight bearing zone, and replaced with a relatively normal bone. For angulation osteotomies, good results were found in lesion size less than 30% of the femoral head or the combined necrotic angle on antero-posterior and lateral view less than 200°. Results were

Appendix

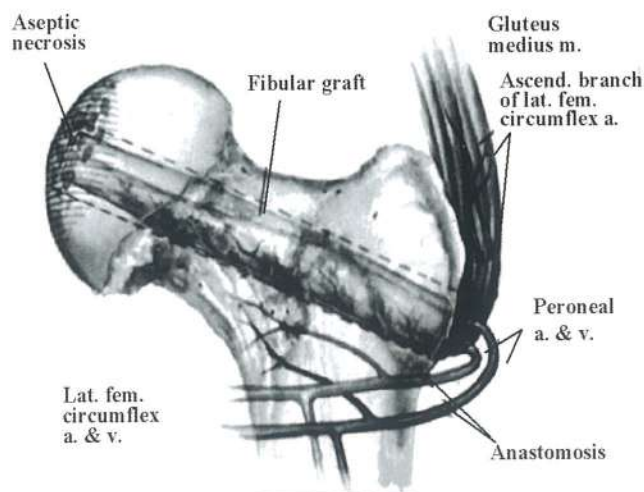


Figure 1. Free vascularized fibular grafting.

variable but some studies have shown good results for Ficat stage II and early stage III avascular necrosis.

Besides angulation osteotomy, Sugioka also devised a rotational osteotomy by rotating the head and neck anteriorly. Reports had shown 95% success rate for a mean of 5 years in the hips where the intact area of the posterior surface of the head is large⁴⁰. However, European studies have been poor. In a 2005 study, 26 hips in 22 consecutive patients were followed up for 8.7 years (range 6.6 to 10 years) and the clinical survival rate was only 56% after 7 years (95% C.I. 36-76%)³².

Late treatment of avascular necrosis

1. Surface replacement is useful in that it serves to delay the need for total hip replacement in patients with Ficat stages III or IV avascular necrosis. It is an effective interim procedure for the management of patients with Ficat stage III or early stage IV disease with a lesion not amendable to other treatment options except a total hip replacement. The most popular surface replacement in the United States was the THARIES (Total Hip Articular Replacement using Internal Eccentric Shells), designed by Amstutz et al.² but the failures were evident within the first 5 years of follow up³⁶.

2. Arthrodesis is an option in younger patients with high functional demands, who desires a single "permanent" procedure rather than a total hip replacement with the need for revisions in the future. But few of these are performed because of bilateral involvement of femoral heads in 50-80% of cases. Hence, it is important that the contralateral hip be ruled out of avascular necrosis before embarking on fusion. Other contraindications include significant ipsilateral knee and spinal pathology.

3. Endoprostheses are generally indicated in individuals with advanced disease, but with sparing of the acetabulum. However, if we compare endoprostheses with total hip replacements, results favour the latter²³.

4. Total hip replacement is the most definitive treatment of choice. Past reports have been disappointing but with improvements in the components and techniques, success rates of total hip replacement have increased tremendously. Recent literature indicated better results at short and medium term follow up.

Post-operative therapy

Early ambulation, prophylactic antibiotics (especially for prosthetic implants), and analgesia are important areas which need to be taken into consideration to ensure that patients can make an early recovery.

Physiotherapy is crucial during this period, and the patient should be encouraged to take it seriously.

Case Study

Case 1

Clinical presentation: AMBI was a 43-year old Malay gentleman, with no significant background history of note, presented to CGH on Feb 2004 with a 6-month history of progressive, sharp and intermittent left-sided hip pain,

which was worse on movement and relieved by rest. It was also associated with a left groin swelling and significant impairment in motion. He did not experience numbness, or radiation of the pain and remained afebrile. Systemic review was unremarkable. There was no history of trauma, steroid administration, alcohol consumption or deep sea diving.

Clinically, he had an antalgic gait, tenderness over the left hip, with limited range of motion. Left hip flexion (0°-90°) and rotation was impaired. Right hip movement was normal. Sensation and pulses were present. Examination of the other systems was unremarkable.

Investigation: Feb 04: MRI investigation of the hips showed left femoral head flattening and deformity. The outline was irregular and had heterogeneous mixed intensity. Effusion was also significant. Right femoral head was normal in shape and outline with no effusion. However, impression was that of early changes of avascular necrosis of the right femoral head.

As such, a diagnosis of Ficat stage III and stage I avascular necrosis of the left and right femoral heads was made respectively. *Refer to appendix.* Figures 2 and 3.

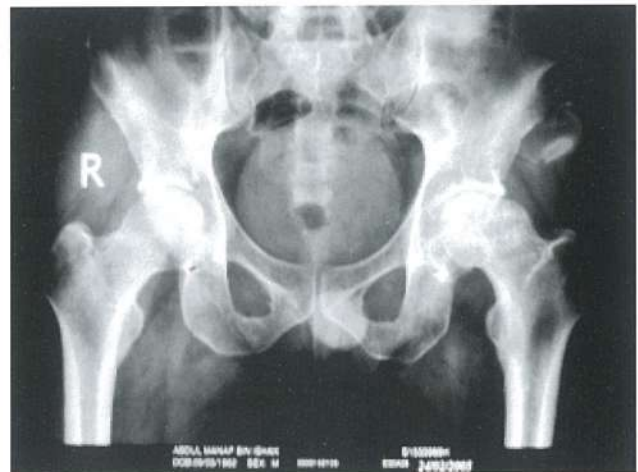

Figure 2. Case 1. Ficat stage I AVN.

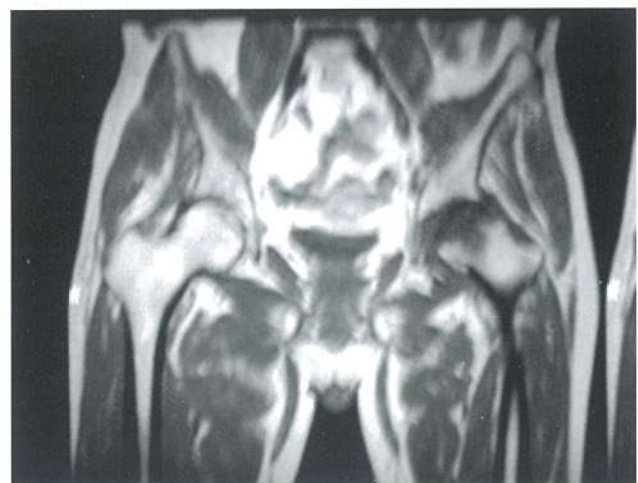

Figure 3. Case 1. Left Ficat stage III AVN.

Management: He was readmitted on March 2004 for elective core decompression (Figure 4) of the right femoral head (pre-collapsed Ficat stage I avascular necrosis). Post-operatively, it was uneventful and he underwent rehabilitation satisfactorily. In view of a Ficat stage IV

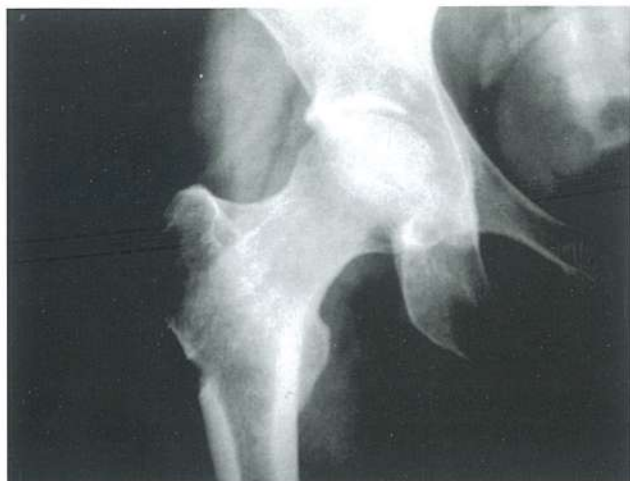

Figure 4. Case 1. Right core decompression without bone graft.

femoral avascular necrosis, he was also educated on the possibility of having a left total hip replacement in the near future.

One month later, he slipped and fell on his buttocks while walking on crutches at home. He then experienced right hip pain and was unable to ambulate thereafter. Radiological findings showed a right subtrochanteric fracture (Figure 5), and open reduction and internal fixation was performed.

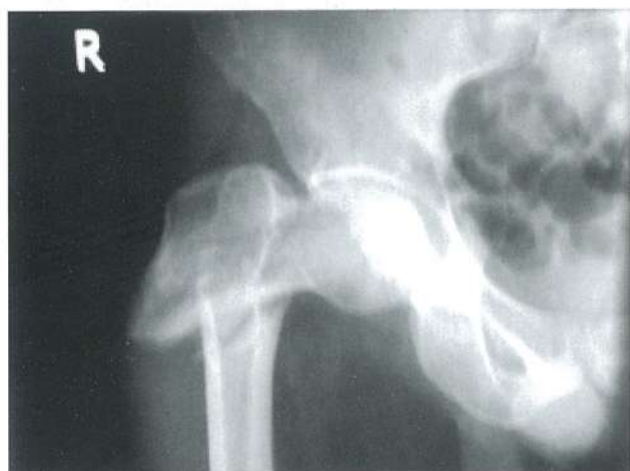

Figure 5. Case 1. Subtrochanteric fracture of left femur.

Case 2

Clinical presentation: OSF was a 22-year old national serviceman, naval diver, who presented to CGH on Oct 2003 complaining of left groin and hip pain for 2 month duration. Systemic review was unremarkable. He had no significant past history of note and has not been on any long term medication (especially in the local context where the use traditional Chinese medicine has been known to sometimes contain steroids). There was no history of significant trauma except for a history of regular runs during his routine training in the army. Neither was there a habit of regular alcohol consumption.

Clinically, the only significant findings involved were found in the left hip, with no evidence of poly-articular or extra-articular involvement. In the left hip, there was a limitation (by pain) in the range of movement, in particular internal and external rotation. The rest of the examination was unremarkable with no definite tenderness, swelling, redness or warmth. His gait was also noted to be normal.

Investigation: Initially, he was treated conservatively with analgesia, activity modification and physiotherapy. However, his symptoms did not improve.

Dec 03: Inflammatory markers were not suggestive of an inflammatory joint pathology. As such, a bone scan was ordered and revealed increased tracer activity at the left femoral head and acetabulum in the delayed phase, suggestive of avascular necrosis or a stress injury of the left femoral head with ongoing reparative process.

May 04: MRI scan of the hip (Figure 6) was ordered

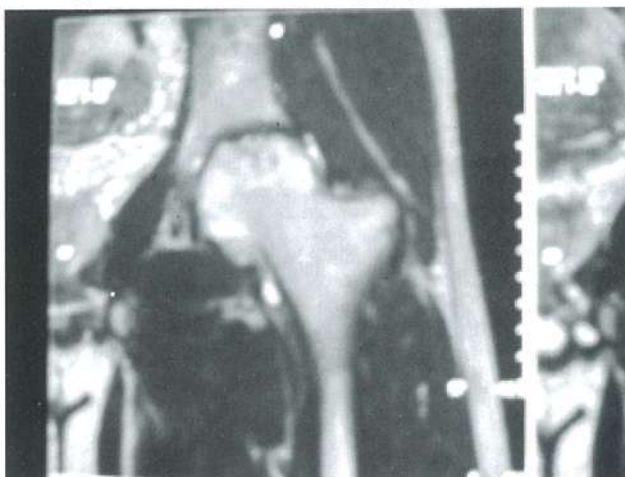


Figure 6. Case 2. MRI confirmed a Ficat stage II AVN.

and confirmed the diagnosis of avascular necrosis of the left femoral head as evidenced by decreased signal density in the antero-superior aspect of the femoral head. X-ray was repeated and now showed evidence of subchondral cyst formation, making it a stage II disease (Figure 7)

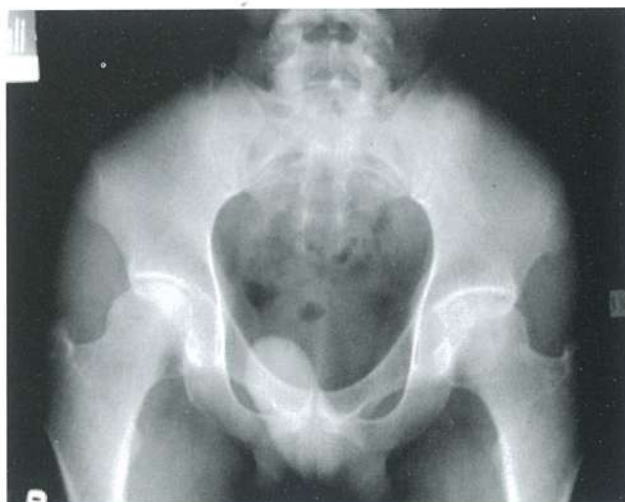

Figure 7. Case 2. Right Ficat stage II AVN.

Management: In view of his young age and early stage of the disease, conservative treatment together with core decompression was chosen and agreed by the patient, hence Mr. OSF underwent an elective core decompression and bone grafting using a fibular allograft (Figure 8) on May 04.

His post-operative recovery was uneventful and rehabilitation notes noted that there was still a limited (by pain) range of motion 0-90°. He was subsequently discharged on the 1st day post-op day with "non-weight bearing" status with the help of crutches.

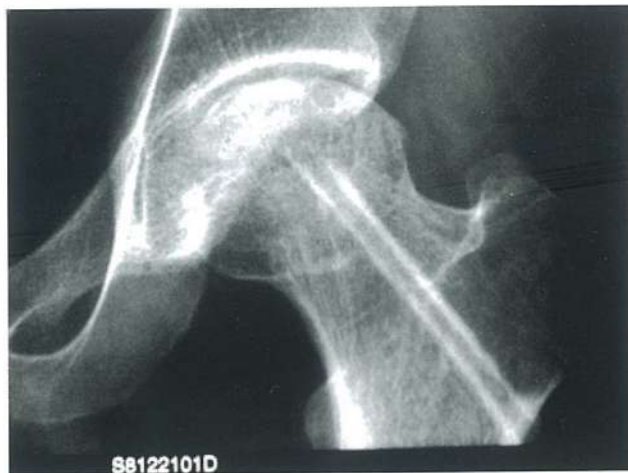

Figure 8. Case 2. Core decompression with fibular allograft inserted into the core track.

Upon regular follow-up, his symptom of pain improved and there was a gradual improvement in his range of motion. More significantly, there was also been a sequential improvement of the disease based on the radiological features seen on sequential X-rays taken post-op. He is currently still on follow up with CGH and has resumed his NS duties.

Case 3

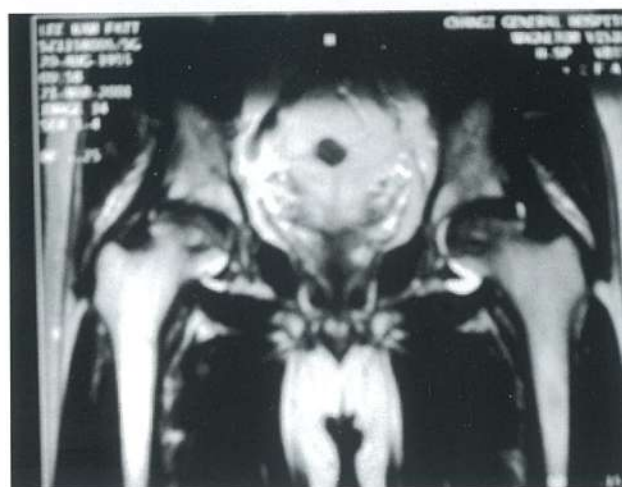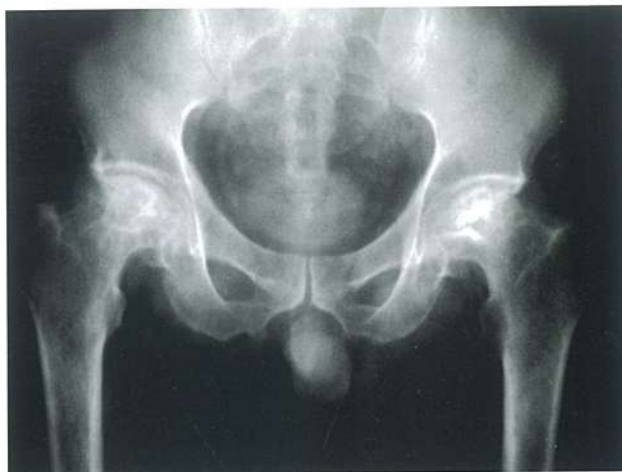Clinical presentation: LKF was a 50 year old Chinese gentleman, with a background history of alcohol abuse (3 bottles of beer a day over the past 20 years) and hypertension, presented with right groin and hip pain for 2 years duration on March 01. It was intermittent and mechanical in nature, which was progressively worsening over the past 2 weeks. There was no history of trauma, diving, or steroid therapy. There was no numbness, or any other joint involvement. Systemic review was unremarkable.

Clinically, he had an antalgic gait, with limited range of flexion, extension, and rotational movement of the right hip. Pulses were present, and sensation was intact. Examination of the other systems was unremarkable.

Four months after the diagnosis of bilateral avascular necrosis of femoral heads in his first admission, he also began experiencing left hip pain, which was intermittent and mechanical in nature. Clinically, range of motion was more restricted in the right than the left. Pulses and sensation were intact. Again, systemic examination was unremarkable.

Investigation: Initially, X-ray showed mild collapse of the femoral head (Figure 9), and MRI showed serpiginous lines and some tram-lines within the head of the femurs on both sides. Both heads were slightly collapsed, with some effusions. Joint spaces were preserved, and features present were all in keeping with Ficat stage III avascular necrosis of both heads (Figure 10).

Management: He was treated conservatively with analgesia and hydrotherapy for a period of time, since he was reluctant on surgical treatment. He also had regular follow up till July 03, when he finally decided to go for surgery because of the intolerable pain.



Figures 9 and 10. Case 3. Ficat stage III AVN of both femoral heads.

He was then admitted for elective left total hip replacement on July 03. Post-operatively, recovery was uneventful and rehabilitation was good. Currently, he is on follow up for the left total hip replacement, and at the same time, monitoring the progression of the avascular necrosis of the right femoral head.

Case 4

Clinical presentation: NLS was a 59 year old Chinese gentleman, with no significant background history of note, presented to CGH on Jan 03 for right hip pain of 3 month history. There was no history of trauma, steroid administration, or alcoholism. Systemic review was unremarkable.

Clinical examination revealed that he had a limited range of motion of his right lower limb. His range of motion are as follows: flexion 80°, extension 10°, internal rotation 10°, external rotation 40°, abduction 45°, adduction 10° and a fixed flexion deformity of 10°. Gait was normal. He was then diagnosed with avascular necrosis of the right femoral head (Figure 11) and he agreed to an elective right total hip replacement (Figure 12).

However, on June 03, he was admitted again for right hip pain for 3 days duration, which radiated to the groin. The pain was aggravated by walking and was not associated with weakness or numbness. He had a fever for 2 days with a maximum temperature of 37.5°C.

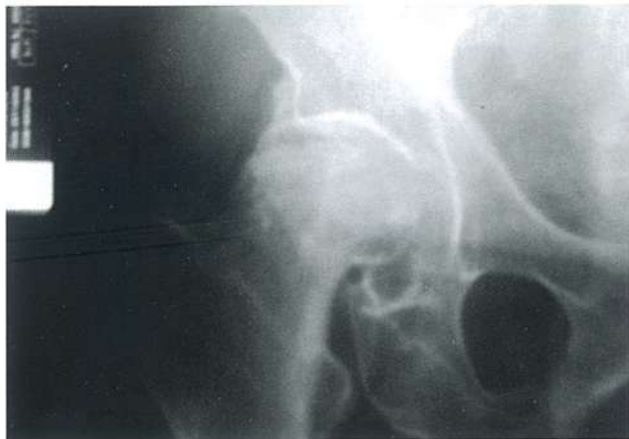

Figure 11. Case 4. AVN of right femoral head.

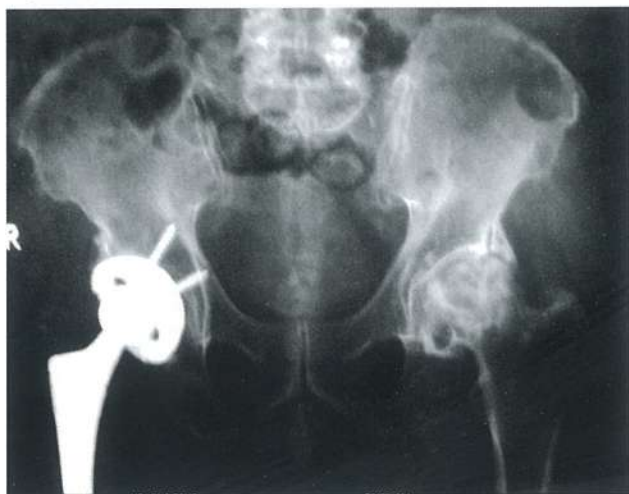

Figure 12. Case 4. Right total hip replacement with a co-existing left Ficat stage III AVN.

Physical examination revealed a right hip scar of the previous THR but there was swelling and erythema in that area. Range of motion was normal. In view of a previous hip replacement, he was diagnosed with septic arthritis and subsequently arthrotomy and wound irrigation was done. Post-op management included IV saline, Cefazolin and Gentamicin.

Subsequently in Feb 05 he was admitted again for left hip pain of 1 week duration. His pain was aggravated by movement, relieved by rest. In the past 2 days, he was unable to ambulate but able to stand with pain. There was no trauma nor fall nor history of alcohol, steroid use or traditional Chinese medicine. Physical examination revealed that he has limited range of motion due to pain and are as follows: flexion 0-10°, internal rotation 0-10°, external rotation 0-10°.

Investigation: X-ray revealed there was a Ficat stage III of the femoral head in the patient's left hip and the femoral head had collapsed. MRI confirmed the findings.

Management: NLS underwent another elective left total hip replacement (Figure 13) and post-op therapy showed that he had recovered full ambulatory status. He was subsequently discharged with analgesic and antibiotic medication. Currently, he is still on follow up.

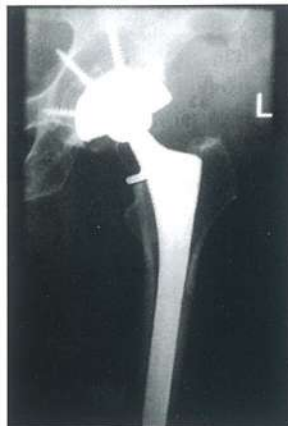

Figure 13.
Case 4. A left total hip replacement.

DISCUSSION

From the cases above, one can notice the clinical presentation of avascular necrosis of the femoral head. Generally, patients would present with hip or groin pain, which is mechanical in nature. At the same time, it is necessary to look out for possible risk factors, but as one can see, cases can be idiopathic. Clinically, they exhibit an antalgic gait, with limited range of motion of the affected hip. There is usually bilateral involvement of the heads of femur in 50-80% of cases, and this is consistent with the case studies.

MRI is the preferred choice of imaging, especially in the detection of early avascular necrosis so that early measures can be implemented to improve the prognosis. It is able to give a definitive diagnosis of osteonecrosis, even though X-rays are also able to pick up abnormalities of the hip in some instances. Looking at the case studies, MRI has certainly been an indispensable imaging tool in orthopedic practice.

With regards to the management of osteonecrosis, treatment depends mainly on the staging of the disease, as well as the general status of the patient. Generally, symptomatic treatment, core decompression with or without bone graft, osteotomy, and free vascularized fibular grafting is indicated in pre-collapsed femoral heads (Ficat stages I and II).

In cases 1 and 2, core decompression was adopted in the treatment in view of early stages of osteonecrosis, and the patients experienced prompt pain relief from the procedure. However, in case 2, a fibular allograft was also used to provide a mechanical support unlike case 1. Subsequently, the patient in case 1 with core decompression without bone grafting had a subtrochanteric fracture after a fall at home. This is a known complication of core decompression. In late stages of osteonecrosis, treatment would include surface replacement, arthrodesis, endoprosthesis, and total hip replacement. Cases 3 and 4 involved advanced stages of avascular necrosis of femoral head. As such, total hip replacement was performed. At the same time, it is important to understand the possible complications of hip replacement such as septic arthritis, which the patient in case study 4 experienced, aseptic loosening, fractures, dislocation, and stiffness. Hence, it is necessary to always assume a septic arthritis in febrile patients, especially immunocompromised individuals, who previously had a prosthesis implant.

CONCLUSION

The progression of the pathological process of avascular necrosis of the femoral head is unpredictable. Therefore, there is a need for intensive research into the patho-etiological process and natural history of this elusive disease. Once there is a greater understanding of the etiology, we can hopefully prevent such a devastating condition from occurring in the first place. Thus, future medical treatment should be aimed at the causes of avascular necrosis so that pre-operative measures can be initiated early.

As we progress into the 21st century, it is also important to establish better methods of diagnostic imaging and treatment. Additional refinements of magnetic resonance imaging may allow more accurate methods of staging the disease. More studies are also needed to optimize the use of pharmacological agents, which include vasodilators, fibrinolytic and lipid lowering drugs.

With advancements made in stem cell research, the possibility has also been raised that bone marrow containing osteogenic precursors implanted into the necrotic lesion could be of benefit in this condition. Indeed, bone

marrow contains adult stem cells, such as haematopoietic stem cells, mesenchymal stem cells and pluripotent stem cells, which might possess osteogenic properties. The efficacy of bone marrow implantation into the osteonecrotic zone has been studied in two prospective trials. Other non-invasive methods of treatment such as electrical stimulation could be refined to increase its efficacy, and even improve operative treatment by using it as an adjunct, together with cytokines to promote early recovery. Current technologies in tissue engineering have their limitations, and there would certainly be issues and future challenges. It may seem simple to produce a tissue-engineered product in the laboratory, but it is a different thing all together to produce hundreds of products of consistent quality for clinical use. New technologies need to be discovered and invented.

Indeed, tissue engineering is likely to create an impact on the evolution of orthopedic implants.

Therefore, it is paramount that we have an increased awareness on this debilitating condition, so that earlier detection and management can be implemented. Ultimately, we hope to be able to restore the quality of life and help the individuals to regain their functional status.

REFERENCES

1. Aaron RK, Ciombar DM, Jolly G. Stimulation of experimental endochondral ossification by low-energy pulsing electromagnetic fields. *J. Bone and Min. Res.* 1989; 4:227-233.
2. Amstutz HC, Sew Hoy AL, Clarke IC. UCLA anatomic total shoulder arthroplasty. *Clin Orthop* 1981; 155:7-20.
3. Arlet J, Mazières B, Thiécher M, Vallières G. The effect of IV injection of naftidrofuryl (Praxilene). In *Intramedullary Pressure in Patients with Osteonecrosis of the Femoral Head. Bone Circulation and Bone Necrosis*, pp.405-406. Edited by J. Arlet and B. Mazières. Berlin, Springer, 1990
4. Buckley PD, Gearen PF, Petty RW. Structural bone-grafting for early atraumatic avascular necrosis of the femoral head. *J. Bone Joint Surg.* 1991; 73-A:1357-1364.
5. Catterall A. The natural history of Perthes' disease. *J Bone Joint Surg.* 1971; 53B:53-57.
6. Chandler HP, Reineck FT, Wixson RL, McCarthy JC. Total hip replacements in patients younger than 30 years old. A 5-year follow up study. *J. Bone Joint Surg.* 1981, 63-A:1426-1434.
7. Dutton RO, Amstutz HC, Thomas BJ, Hedley AK. Tharies surface replacement for osteonecrosis of the femoral head. *J. Bone Joint Surg.* 1982, 64 A:1225-1237.
8. Fairbank AC, Bhatia D, Jinnah RH, Hungerford DS. Long-term results of core decompression for ischaemic necrosis of the femoral head. *J Bone Joint Surg.* 1995;77 (1):42-9.
9. Genez, BM, Wilson MR, Houk RW, Weiland FL, Unger HR Jr, Shields NN, Rugh KS. Early osteonecrosis of femoral head: detection in high-risk patients with MR imaging. *Radiology*, 1988; 168:521-524.
10. Glueck CJ, Freiberg R, Tracy T, Stroop D, Wang P. Thrombophilia and hypofibrinolysis: Pathophysiologies of osteonecrosis. *Clin Orthop.* 1997; 334:43-56.
11. Glueck, CJ, Freiberg R, Glueck HI, Stroop D, Tracy T, Hamer T. Idiopathic osteonecrosis, hypofibrinolysis, high plasminogen activator inhibitor, high lipoprotein(a), and therapy with stanozolol. *Clin. Res.* 1993; 41:661A.
12. Glueck CJ, Freiberg R, Glueck HI, Stroop D, Tracy T, Hamer A. Idiopathic osteonecrosis, hypofibrinolysis, high plasminogen activator inhibitor, high lipoprotein(a), and therapy with stanozolol [abstract]. *ARCO Proc.*, 5:65, 1994.
13. Hauzeur JP, Pasteels JL, Schoutens A, Hinsenkamp M, Appelboom T, Chochrad I, Perimutter N. The diagnostic value of magnetic resonance imaging in non-traumatic osteonecrosis of the femoral head. *J. Bone and Joint Surg.* 1989; 71-A:641-649.
14. Hungerford DS, Jones LC. Diagnosis of osteonecrosis of the femoral head. In *Bone Circulation and Vacularization in Normal and Pathological conditions*, pp.265-275. Edited by A Schoutens, J Arlet, JWM Gardeniers and SPF Hughes. New York, Plenum Press, 1993.
15. Jones JP Jr. Alcoholism, hypercortisolism, fat embolism and osseous avascular necrosis. In *Idiopathic Ischemic Necrosis of the Femoral Head in Adults*, p.112. Edited by W. M. Zinn. Stuttgart, Georg Thieme, 1971.
16. Jones JP Jr. Intravascular coagulation and osteonecrosis. *Clin Orthop.* 1992; 277:41-53.
17. Jones JP Jr. Etiology and pathogenesis of osteonecrosis. *Semin Arthrop* 1991; 2:160-168.
18. Jones JP Jr. Risk factors potentially activating intravascular coagulation and causing non-traumatic osteonecrosis. In *Urbaniak JR, Jones Jr JP(eds). Osteonecrosis. Etiology, diagnosis and treatment.* Rosemont, IL, American Academy of Orthopedic surgeons 89-96, 1997

19. Judet H, Gilbert A. Long term results of free vascularized fibular grating for femoral head necrosis. *Clin Orthop* 2001; 386:114-119.
20. Kay RM, Lieberman JR, Dorey FJ, Seeger LL. Inter- and intra-observer variation in staging patients with proven avascular necrosis of the hip. *Clin Orthop* 1994; 307:124-129.
21. Kokubo T, Takatori Y, Ninomiya S, Nakamura T, Kamogawa M. Magnetic resonance imaging and scintigraphy of avascular necrosis of the femoral head. Prediction of subsequent segmental collapse. *Clin Orthop* 1992; 277:54-60.
22. Lang P, Jergesen HE, Moseley ME, Block JE, Chafetz NL, Genant HK. Avascular necrosis of the femoral head: high-field-strength MR imaging with histologic correlation. *Radiology*, 1988; 169:517-524.
23. Lee SB, Nobuhiko S, Katsuya N, Minoru M, Kenji O. Comparison between bipolar hemiarthroplasty and THA for osteonecrosis of the femoral head. *Clin Orthop* 2004; (424):161-165.
24. Mankin HJ. Non-traumatic necrosis of bone (osteonecrosis). *N Engl J Med* 1992; 326:1473-1479.
25. Masuda T, Matsuno T, Hasegawa I, Kanno T, Ichioka Y, Kaneda K. Results of transtrochanteric rotational osteotomy for non-traumatic osteonecrosis of the femoral head. *Clin Orthop*. 1988; 228:69-74.
26. Meyers MH. Osteonecrosis of the femoral head. Pathogenesis and long-term results of treatment. *Clin Orthop*. 1988; 231:51-61.
27. Meyers MH, Covery FR. Grafting procedures in osteonecrosis of the hip. *Sem. Arthroplasty* 1991; 2:189-197.
28. Mitchell DG, Rao VM, Dalinka MK, Spritzer CE, Alavi A, Steinberg ME, Fallon M, Kressel HY. Femoral head avascular necrosis: correlation of MR imaging, radiographic staging, radionuclide imaging, and clinical findings. *Radiology* 1987; 162:709-715.
29. Mont MA, Carbone JJ, Fairbank AC. Core decompression versus non-operative management for osteonecrosis of the hip. *Clin Orthop Relat Res* 1996; (324):169-78.
30. Ono K, Sugioka Y. Epidemiology and risk factors in osteonecrosis of the femoral head. Bone circulation and vascularization in normal and pathological conditions: pp243-248,1993
31. Petri M, Mont MA, Hungerford DS. Pharmacological agents for the treatment of early stages of avascular necrosis. Unpublished.
32. Rijnen WH, Gardeniers JW, Westrek BL, Buma P, Schreurs BW. Sugioka's osteotomy for femoral-head necrosis in young Caucasians. *Int Orthop*. 2005 Apr 14; [Epub ahead of print]
33. Rosenwasser MP, Garino JP, Kiernan HA, Michelsen CB. Long term follow up of thorough debridement and cancellous bone grafting of the femoral head for avascular necrosis. *Clin. Orthop*. 1994; 306:17-28.
34. Scher MA, Jakin I. Intertrochanteric osteotomy and autogenous bone-grafting for avascular necrosis of the femoral head. *J. Bone and Joint Surg*. 1993; 75-A:1119-1133.
35. Solacoff D, Mont MA, Krackow KA. Uncemented total hip arthroplasty in patients less than 45 years with avascular necrosis. *Orthop. Trans.* 17:1085, 1993-1994
36. Steinberg ME: Evolution and development of surface replacement arthroplasty. *Orthop Clin North Am* 1982; 13:661-662.
37. Steinberg ME, Hayken GD, Steinberg DR. The "conservative" management of avascular necrosis of the femoral head. In *Bone Circulation*, pp.334-337. Edited by J Arlet, RP Ficat, and DS Hungerford. Baltimore, Williams and Wilkins, 1984
38. Steinberg ME, Hayken GD, Steinberg DR. A quantitative system for staging avascular necrosis. *J. Bone and Joint Surg*. 1995; 77-B(1):34-41.
39. Stulberg BN, Levine M, Bauer, TW, Belhobek G, Pflanze W, Feiglin DHL, Roth AL. Multimodality approach to osteonecrosis of the femoral head. *Clin Orthop*. 1989; 240:181-193.
40. Sugioka, Y.; Katsuki, I.; and Hotokebuchi, T: Transtrochanteric rotational osteotomy of the femoral head for the treatment of osteonecrosis. Follow up statistics. *Clin Orthop* 1982; 169:115.
41. Thickman D, Axel L, Kressel HY, Steinberg M, Chen H, Velehick M, Fallon M, Dalinka M. Magnetic resonance imaging of avascular necrosis of the femoral head. *Skel. Radiol*. 1986 15:133-140.
42. Wang TY, Avlonitis EG, Relkin R. Systemic necrotizing vasculitis causing bone necrosis. *Am. J. Med*. 1988; 84:1085-1086.
43. Zizic TM, Hungerford DS. Avascular necrosis of bone. In *Textbook of Rheumatology*, edited by WN Kelley, ED Harris, S Ruddy, and C Sledge. Ed.2, pp.1689-1710. Philadelphia, W. B. Saunders, 1985