

Blue Bubbles, Bubbly Bones; Maffucci Syndrome, A Case Report.

Siti Nur Fudhlana AA; Mohd. Zaharial M; Che SS; Hau MA
Department of Orthopaedics, Hospital Raja Perempuan Zainab II, Kelantan

INTRODUCTION:

Maffucci syndrome is a rare congenital, non hereditary disease characterized by multiple hemangiomas and enchondromas. This disease may associate with skeletal deformities

CASE REPORT:

We report a case of 20 years old male who presented with asymptomatic, multiple soft tissue swelling of the hands since adolescence. Clinical examination revealed multiple bluish soft and painless nodules with a vascular appearance. He also presented with bony deformity of phalanges of left hand. Plain radiograph studies revealed multiple bony lesions suggestive for enchondromas, with area of phleboliths of soft tissue of hand. Similar findings were observed in his skeletal survey.

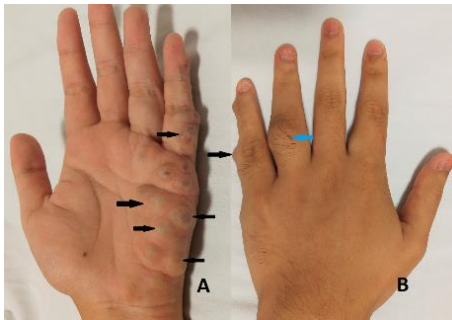


Figure 1: multiple hemangioma (black arrow), bony deformity (blue arrow).

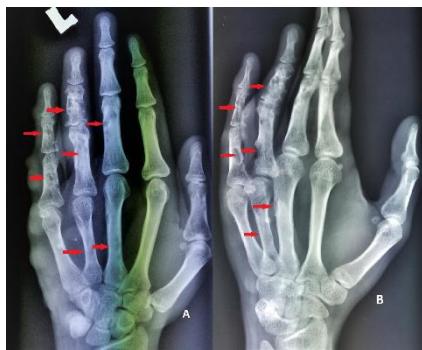

Figure 2: multiple well define bony lesions. (red arrow)

CONCLUSION :

Maffucci syndrome is characterized by multiple enchondromatosis with hemangiomatosis, usually affecting bones of the hands with unknown etiology. Clinically, affected individual is asymptomatic; disease will manifest early in childhood, and lesions is slow but progressively growing. Enchondromas are benign cartilaginous tumours, it may complicated with bony deformities and pathological fractures. In case of maffucci syndrome, this enchondromas may transform into secondary chondrosarcomas, which usually occurs approximately 52-57% of the cases.¹ Maffucci syndrome also is associated with other neoplasm (primary brain tumor, cholangiocarcinoma).¹⁻³ There is no treatment to halt its progression, thus management is focused at symptomatic relief and regular follow up for early detection of malignant transformation.^{1,2,4}

REFERENCES:

1. Herget GW.et al. Insights into Enchondroma, Enchondromatosis and the risk of secondary Chondrosarcoma. Review of the literature with an emphasis on the clinical behaviour, radiology, malignant transformation and the follow up.2014.
2. Prokopchuk et al. Maffucci syndrome and neoplasms : a case report and review of the literature. *BMC Res Notes*.2016.
3. Brien EW.et al. Benign and malignant cartilage tumors of bone and joint : their anatomic and theoretical basis with an emphasis on radiology, pathology and clinical biology. II . Juxtacortical cartilage tumors. *Skelet Radiol*.1999
4. Gao H.et al. Maffucci syndrome with unilateral limb : a case report and review of the literature.2013.