

# A Rare Case Of Recurrent Squamous Cell Carcinoma Of Thumb Nail Bed: A Case Report

Mohd Kamel MJ; Kamel MJ; Sahran Y; Hanifah J; Faisham WI

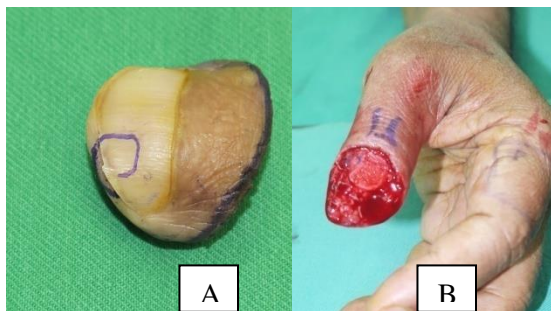
Department of Orthopaedics, Hospital Universiti Sains Malaysia, Kelantan

## INTRODUCTION:

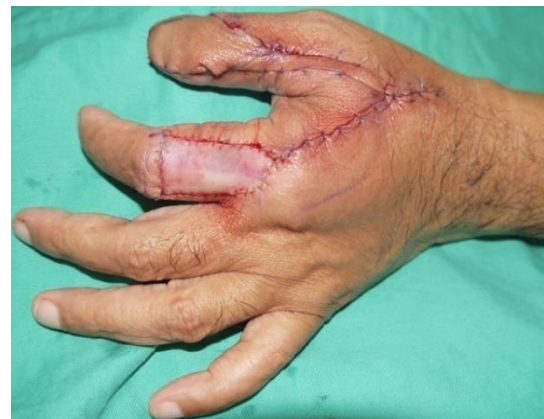Primary malignant subungual tumors are rare, although of these, Squamous Cell Carcinoma (SCC) is the most frequent. Diagnosis is frequently delayed by the relatively nonspecific clinical presentation, confusion with benign inflammatory conditions such as paronychia, pyogenic granuloma, or a common wart.<sup>1</sup> Diagnosis is only possible by biopsy and histopathological examinations.

## REPORT:

We report a case of 62-years-old gentleman who presented with painful swelling over his left thumb nail-bed for two years, It was associated with intermittent contact bleeding. He didn't have any constitutional symptoms. On examination, there was a non tender mass sized 1x0.5cm over the nail bed (**figure 1**). He presented to a clinic where the tumor was excised. However, the tumor recurred and second surgery was done in another hospital. He was referred to us after the histopathology was reported as squamous cell carcinoma. We performed wide local excision for the tumor recurrence and soft tissue reconstruction of the thumb to cover the defect (**Figure 2**).



**Figure 1;** Entire nail bed (A) and dorsal part of distal phalanx was excised (B).



**Figure 2;** Soft tissue reconstruction using the 1<sup>st</sup> dorsal metacarpal artery island flap and full thickness skin graft from left inner arm.

## CONCLUSION:

We would like to highlight the importance of proper assessment and role of histopathology in the diagnosis of SCC. A biopsy is essential in all patients with any chronic nail condition that fails to respond to conventional treatment.<sup>2</sup> This case showed that underlying malignancy can mimic a benign nail pathology. Adequate local clearance is mainstay of treatment. The 1st dorsal metacarpal artery island flap offers a sensate, pliable and versatile coverage for small to moderate sized thumb defects. Moreover, it provides good functional and esthetic outcomes with minimal donor site morbidity.

## REFERENCES:

1. Tirpude.BH et al. IntSurg J. 2015 Feb;2(1):79-81.
2. Swagataet. al. Journal of cutaneous aesthetic Surg2017 Jan-Mar; 10(1): 59–60.