

# Distal Femur Fracture Treated With Locking Plate: 3 Years Single Center Review

Muhammad Najmi AG; Wong YJ; Nazrin; Leong YH; Ruben JY

Department Of Orthopaedic, Hospital Serdang, Selangor

## INTRODUCTION:

Distal femur fracture has a bimodal occurrence: in young people due to a high-energy trauma and in older people related to a low-energy trauma. The aim of this study was to evaluate the fracture healing, functional outcome and complication following open reduction and internal fixation (ORIF) with locking compression plates (LCP) in this two-different age group.

## METHODS:

A retrospective study was conducted on patients with distal femur fracture operated by using locking plate between year 2015 and 2017. Patient with open fracture and pathological fracture was excluded. Data regarding age, range of motion of knee, time to union, infection and complication due to the surgery were analysed.

## RESULTS:

A total of 46 patients with distal femur fracture managed surgically via LCP. The mean age was 56.5-year-old (range, 16-86 years). 48% (22) patients was less than 60-year-old and 52% (24) patients was more than 60 years old. 73% (22) from younger age group was alleged motor vehicle accident while 79% (19) from old age group was alleged fall. The mean time to union for each younger and older age group 9.5 months and 11.3 months (figure 1). 7% (3) patients complicated with infection and 4% (2) with non-union. 55% (12) young patients had range of motion more than 120 degree after bony union while 41% (10) in old patient.

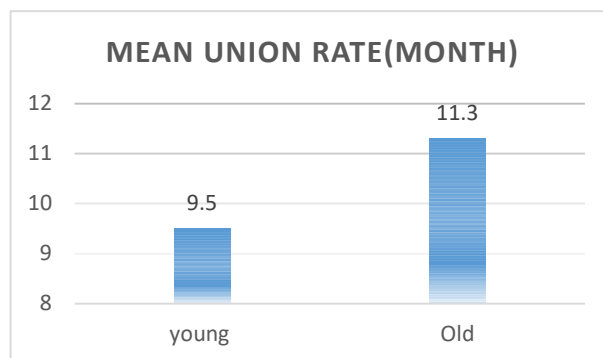


Figure 1

## DISCUSSIONS:

Locking plate system has been commonly used in distal femur fracture. It provides strong and stable fixation, while reducing complications to minimum. Hence, early mobilization and more rapid healing. Results of our study suggested that the use of LCP in distal femur fracture results in good union rate. Time to union, range of motion after union is better in younger age group.

## CONCLUSION:

Distal femur fractures, if fixed in proper fashion following the basic principle, distal femur LCP remain implant of choice for all varieties of distal femur fracture either in younger or older age group.

## REFERENCES:

1. Jagandeep SV, Sudhir KG, Parmanand G, Vivek J, Jagdeep S, Sudhir R. Distal Femur Locking Plate: The Answer to All Distal Femoral Fractures. *Journal of Clinical and Diagnostic Research*. 2016;10:01-05.
2. EJ Yap, AS Deepak. Distal Femoral Locking Compression Plate Fixation in Distal Femoral Fractures: Early Results. *Malaysia Orthopedic Journal. International Journal of Surgery Case Reports*. 200;01:12-17.