

Expanding The Hourglass: Early Outcome of Tibial Bone Splitting Procedure In A Suboptimal Bony Consolidation After Bone Transport

¹Ghazali MN; ¹WJ Tee, ¹Zayzan KR, ¹Towil B

¹Department of Orthopaedics and Traumatology, Hospital Sungai Buloh, Malaysia

INTRODUCTION:

A recent novel technique of bone splitting and bone grafting was described by Huang et al¹ for hypoplastic bony regenerate following distraction osteogenesis. We reported an early outcome of a modified bone splitting procedure in a suboptimal hourglass tibial consolidation.

REPORT:

A 31-year-old gentleman sustained an open right tibial plateau fracture (Schatzker VI) with segmental bone loss (Gustillo 3B) and was treated initially by corticotomy and bone transport via Ilizarov external fixator. At 2 years post-operatively, the tibial regenerate consolidated in an hourglass fashion and the width was less than half of the normal tibia. Biomarkers for infection and systemic causes were unremarkable.

Patient underwent bone splitting, iliac bone grafting and revision of construct (Figure 1). We split the tibial cortices longitudinally perpendicular to each other by creating multiple holes using low speed drilling followed by

osteotomy to enlarge the tibial canal enough to insert autologous iliac bone graft. Evidently at 8 weeks post-operatively, plain radiographs showed 43% increment of the tibia diameter (from 1.24 cm to 2.86 cm). (Figure 2 & 3)

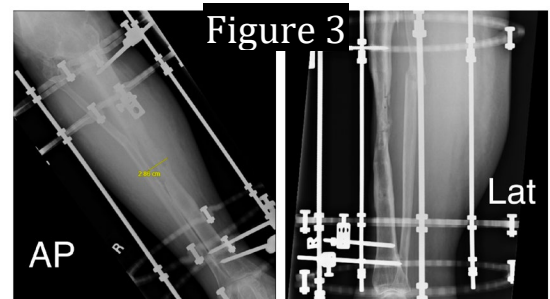
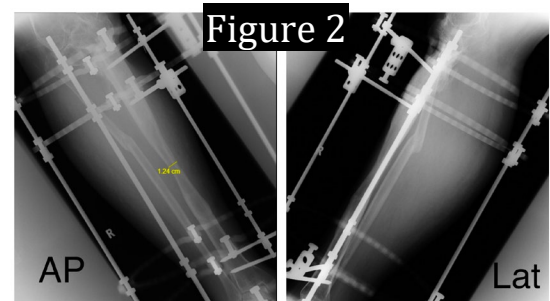


Figure 2: Right Tibia Pre-operation
Figure 3: Right Tibia Post-operation

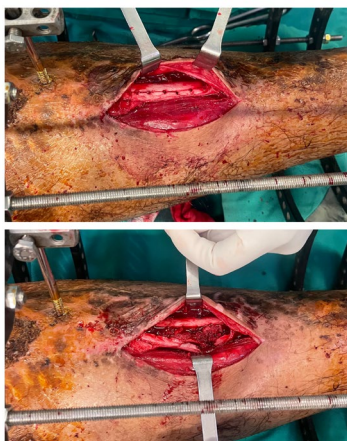


Figure 1: Modified intra operative technique in bone splitting and bone grafting procedure

CONCLUSION:

Bone splitting and bone grafting for hypoplastic bony regenerate or consolidate following distraction osteogenesis offers a safe & simple procedure with favorable outcome.

REFERENCES:

¹Lee HS, Tasarib R, Hamzah FC, Halim AH. A Novel Technique-Bone Splitting and Bone Grafting in an Hourglass-shaped Bone Following Distraction Osteogenesis. *Strategies Trauma Limb Reconstr.* 2020;15(3):174-178. doi:10.5005/jp-journals-10080-1509