

Disastrous Moments In Managing Ligamentum Flavum Ossification. How We Did It? A CASE REPORT

¹Chanddrasuriya K; ¹Sharfuddin AI, ²Thuraikumar K, ¹Satriya SHA

¹Department of Orthopaedic, Hospital Tengku Ampuan Rahimah, Klang

²Department of Orthopaedic, Hospital Sungai Buloh

INTRODUCTION:

Dural tears are among the most commonly seen complication in spine surgery. Dural tear is a dreaded complication in lumbar surgery because of the cascade of serious secondary effects, most particularly dural fistula, intracranial hematoma, meningitis can set off.

REPORT:

We are reporting a case of 38 year-old woman, who presented with low back pain, right lower limb numbness without neurological deficit. MRI lumbosacral showed, extensive ligamentum flavum hypertrophy causing lumbar spinal canal stenosis worst at L2/L3 level. We proceeded with posterior spinal instrumentation from T11-L4, laminectomy L1 to L3 and posterolateral fusion. Intraoperatively, thinning of dura in the region of stenosis led to incidental durotomy at the junction of L1/L2. Primary closure was done with suture and autologous fat. Postoperatively, persistent clear fluid discharge from drain which led to CT myelogram of lumbosacral to look for cerebrospinal fluid (CSF) leak which showed large defect along the posterior dura at the level of T12 to L3. Combined with neurosurgical team, reconstruction of dural defect measuring 2x8cm was done using fascia lata autograft. Post operatively, the CSF leak was resolved and patient was discharged well.

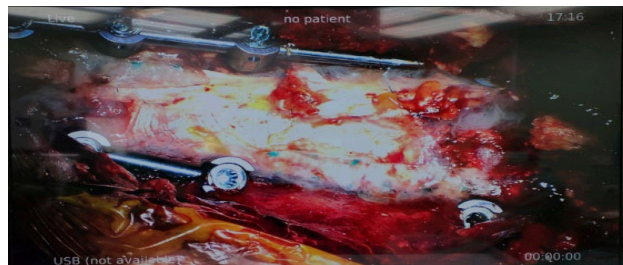
DISCUSSIONS:

In our experience, large dural tear where primary repair is not possible can be reconstructed with autologous substitute like fascia lata autograft harvested for duraplasty¹. This will prevent persistent CSF leak and avoid complications serious complications including CSF fistula or the formation of the pseudocyst, which places the patient at risk of meningitis, nerve root entrapment, cranial nerve palsy, and mass effect¹.

Figure 1: Dura graft with fascia lata



Figure 2: Repair of Dura with fascia lata



CONCLUSION:

Durotomy can be encountered during the course of spinal stenosis surgery. Fascia lata autologous graft in the treatment of postoperative CSF leakage after spine surgery is an effective method with excellent surgical results.

REFERENCES:

1. Espiritu, M. T., Rhyne, A., & Darden, B. V. (2010). Dural tears in spine surgery. *JAAOS- Journal of the American Academy of Orthopaedic Surgeons*, 18(9), 537-545.