

## Managing Tibia Metaphyseal Bone Defect in Total Knee Arthroplasty

<sup>1</sup>Lik Han Ong; <sup>2</sup>Rutel Ankintay; <sup>2</sup>Jaffar Mohd Shahrul Azuan; <sup>2</sup>Sabaruddin Abdullah; <sup>2</sup>Chun Haw Bong; <sup>2</sup>Kean Tee Tan, <sup>2</sup>Prashant Rao, Reuben, <sup>2</sup>Kamaruddin Faris

<sup>1</sup> Faculty of Medicine & Health Sciences University Malaysia Sarawak Kota Samarahan Sarawak.

<sup>2</sup>Sarawak General Hospital, Kuching Sarawak.

### INTRODUCTION:

Bone defect in the tibia metaphyseal region can present a challenge in both primary total knee arthroplasty (TKA) and revision total knee arthroplasty. In our experience of managing tibia metaphyseal bone defect in total knee arthroplasty (TKA), we use bone cement alone if defect was  $\leq 30\%$  width and  $\leq 5\text{mm}$  deep, cement and screw if depth was 5-10mm, and metal augment if depth was  $> 10\text{mm}$  or width  $> 30\%$ . We would like to report the results of simple algorithm which can provide good or comparative outcome for tibia component in both primary and revision TKAs.

### MATERIALS & METHODS:

In this retrospective study, patients with primary and revision TKAs that have tibia bone defects between January 2009 to May 2018 were included. Their preoperative, postoperative and follow-up radiographs were assessed for loosening, malalignment, implant migration, and scored using The Knee Society Total Knee Arthroplasty Roentgenographic Evaluation and Scoring System.

### RESULTS:

Forty-nine knees of 43 patients were included, of which 35 were primary TKAs and 14 revisions, with mean follow-up period of 77 and 81 months respectively. At the final follow-up, radiolucent line (RLL) was present in 15 knees (31%), of which 14 were categorized as non-significant (8 primary and 6 revisions) and only one that progressed to aseptic loosening and failure requiring revision. One knee required revision for early recurrent dislocation, bringing the total revision to two cases (4.1%).

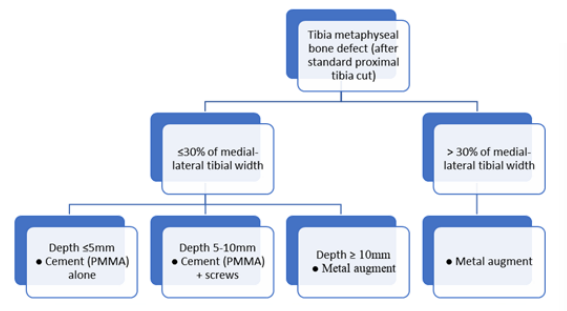


Figure 1: Treatment algorithm for tibia metaphyseal bone defect in total knee arthroplasty.

### DISCUSSIONS:

This algorithm method addressing tibia metaphyseal bone defect in primary and revision surgeries, we achieved satisfactory results with an overall 2-to-11 years revision rate of 4.1%. Our study has limitations of number of subjects, a retrospective design and only radiographic evaluation without clinical scoring. However, we reduced the variables by including only cases done at a single center, one team members, and using only one implant design. We reckoned the study focusing on radiographic evaluation is appropriate for this subject matter because tibia bone defect management in TKA is directly linked to tibial tray stability, longevity, and the tibial tray's coronal as well as sagittal alignment.

### CONCLUSION:

Our simple algorithm of choosing cement, cement and screw, or metal augment to manage tibia metaphyseal bone defect based on width and depth of the defect resulted in favorable outcome in both primary and revision TKAs.