

Retrograde Hindfoot Fusion as Primary Treatment of Complex Ankle Fracture

¹ M.M Zhaiem; ²A.A Rozain ³S.M Lim ⁴Hassan, Idham
Foot and Ankle unit of Orthopedic Department of Hospital Putrajaya

INTRODUCTION:

A hindfoot nail is a powerful load sharing device, to facilitate hindfoot arthrodesis by mechanically sacrificing joint motion at tibiotalocalcaneal region. It is commonly use in treating many chronic and degenerative cases of foot and ankle (e.g Charcot neuroarthropathy, failed joint replacement, arthritic joint, ankle nonunion and many more,). Nowadays, the use of retrograde hindfoot as primary arthrodesis in complex ankle trauma case has continue to gain popularity.

This is a case report of a complex ankle fracture that was referred to our foot and ankle unit and was treated with hindfoot fusion

REPORT:

A 37 years old gentleman was referred to our foot and ankle unit, after an alleged motor vehicle accident sustaining an open dislocation of right ankle with trimalleolar fracture and comminuted right talus fracture. (figure 1). He was planned for retrograde hindfoot fusion as definitive treatment after careful pre-operative planning.

At earlier stages of follow up, there was mild surgical site infection whereby there was loosening of lateral malleolus screw. Patient had to undergo a second look debridement and removal of one screw. Infection was eradicated successfully after a course of antibiotics.

Later on, the patient showed tremendous amount of healing both clinically and radiographically (figure 2). The patient able to walk independently at 5-month post operation with well healed wound

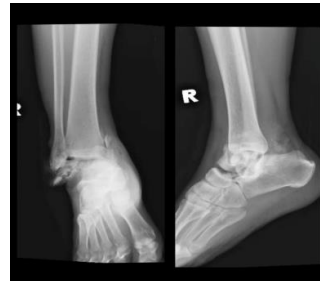

Figure 1: Post trauma x-ray

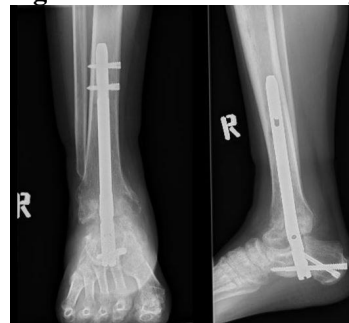


Figure 2: Post operative 5month x-ray

CONCLUSION:

Joint preserving reconstruction using internal fixation is always almost the preferred operative method for ankle fracture and dislocation.

However, in the setting of irreversible severe cartilage with ligamentous injury and high degree of joint and bones damages, a primary hindfoot arthrodesis does have a significant role in surgeon armamentaria, to get the best surgical outcomes. ⁽¹⁾

The use of retrograde hindfoot nail as primary arthrodesis provides an alternative option in treating complex ankle trauma case

REFERENCES:

1. Tarkin et al., University of Pittsburg, Retrograde hindfoot nailing in acute trauma, 2018